

# phinari turnitin result

## 24.06.2022

*by Phinari Final*

---

**Submission date:** 24-Jun-2022 01:51PM (UTC+0700)

**Submission ID:** 1862188616

**File name:** bp\_final.docx (1.01M)

**Word count:** 2310

**Character count:** 14516

## BOWENOID PAPULOSIS WITH CLINICAL FEATURES RESEMBLING CONDYLOMA ACUMINATA: A CASE REPORT

Handelia Phinari<sup>1</sup>, Ni Nyoman Ayu Sutirini<sup>2</sup>

<sup>1,2</sup>Department of Dermatology and Venereology, Bali Mandara General Hospital, Denpasar,  
Bali, Indonesia

\*Correspondence email: handeliaphinari@gmail.com

10

### ABSTRACT

Bowenoid papulosis (BP) is a rare case of sexual transmitted disease caused by HPV 16 that affects the young, sexually active age group. A 39-years-old male complained of warts over the scrotum and left groin that gradually increased in number and size for one year duration. There was history of similar complaint. Dermatology status obtained multiple, small, well-defined, grey-brown papules on the scrotum and left groin. Dermoscopy examination revealed a pigmented papillomatous surface, brown-grey dots linear arrangement at the edges, and widespread dotted vessels. Histopathological examination confirmed Bowenoid Papulosis. Based on clinical findings, Bowenoid papulosis cannot be distinguished from Condyloma Acuminata. Therefore, to confirm the diagnosis histopathological examination should be done. The patient is treated with surgical excision and cauterization. Six months after the procedure, the patient had no complaints or new lesions. Since the development of BP is unpredictable, early diagnosis, adequate treatment, and routine examinations for recurrence and progression of the disease are required.

**Keywords:** Bowenoid Papulosis, Human Papillomavirus, Condyloma Acuminata

9

### INTRODUCTION

Bowenoid Papulosis (BP) is an uncommon sexual transmitted disease (STD) caused by oncogenic Human Papillomavirus (HPV) types, mainly HPV 16, and generally affects the young sexually active age group. Bowenoid papulosis is generally benign and regresses spontaneously within months, but it can persist for years, recur, and transform into invasive squamous cell carcinoma, especially in immunocompromised patients. Bowenoid Papulosis occurs mainly in the third to mid-fifth decades of life with an average age of 31 years old. This disease can affect all gender but is currently more common in women, with an estimate of 5 cases per 100.000 female population. However, the exact prevalence remains unknown.<sup>1,2</sup>

The characteristics of BP are solitary or multiple papules or plaques resembling verrucae. In order to prevent malignant transformation, early diagnosis is required.

Skin biopsy is done to confirm the diagnosis. Histopathological examination revealed a characteristic picture of bowenoid dysplasia with acanthosis characteristically with full-thickness epidermal atypia.<sup>2,3</sup>

Bowenoid papulosis treatments that have been shown to be effective are topical retinoids, imiquimod, 5-fluorouracil, and cidofovir. Surgical management can be done by cryotherapy, electrodesiccation, shave biopsy, surgical excision, interferon injection, and vaporization by laser. Patients with longer duration of lesions, particularly elderly group, should be given more attention because it could be a sign of malignant and requires surgery. Routine examination to rule out carcinoma *in situ*/Squamous Cell Carcinoma (SCC) must be done.<sup>3</sup>

This case was appointed on the basis of Bowenoid Papulosis clinical findings in patient that resembled Condyloma Acuminata. Due to the similar clinical

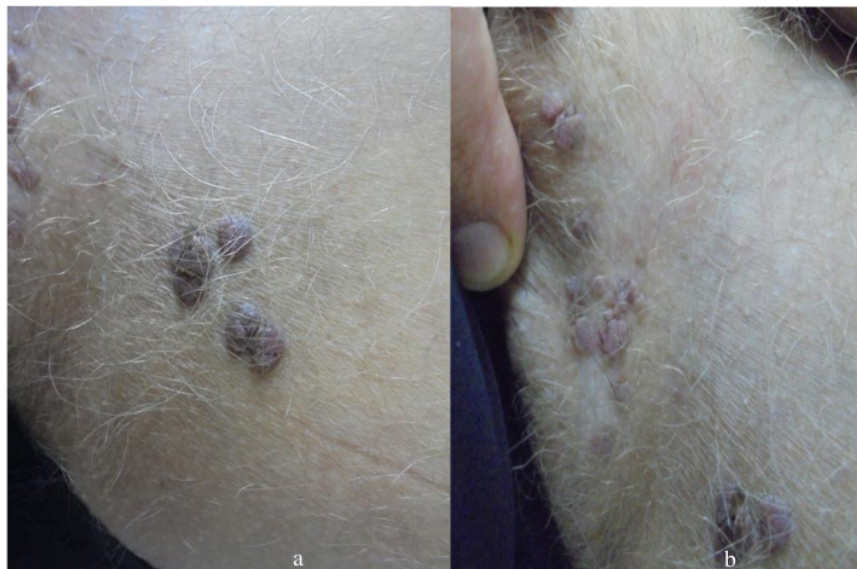morphology, histopathological examination is required to confirm the diagnosis. This is related to the early detection and prevention of potential malignancies which may occurs in BP.

#### CASE DESCRIPTION

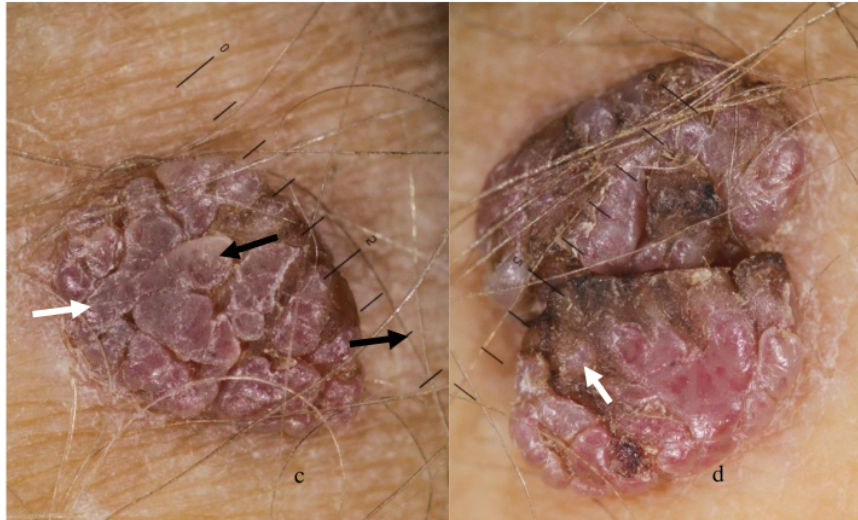
A 39-years-old male presented with warts over the scrotum and left groin of one-year duration. The patient has a history of the similar complaint and has been cauterized one year ago. Currently, the warts are gradually increased in number and size. The patient denies a history of unprotected sexual intercourse. No history leading to immunosuppression or long-term drug intake.

On physical examination, level of consciousness was *compos mentis*, vital signs, and general status was within normal limits. On dermatology examination, there were multiple, small, well-defined, grey-brown papules on the scrotum and left groin. Dermoscopy examination exhibit pigmented papillomatous surface, brown-grey dots linearly arranged at the edges, and widespread dotted vessels.

Based on the history, physical examination, and dermoscopy examination, we make a differential diagnosis of Bowenoid Papulosis, Squamous Cell Carcinoma, and Condyloma Acuminata. The patient is scheduled for an excisional biopsy one week later.



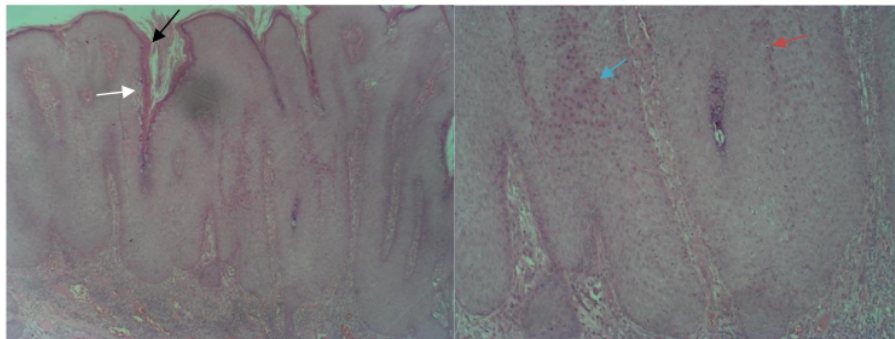
**Figure 1a-b.** multiple small, well-defined, grey-brown papules on the scrotum and left groin.



**Figure 1c-d.** Pigmented papillomatous surface, brown-grey dots linearly arranged at the edges (black arrow), and widespread dotted vessels on dermoscopy examination (white arrow).

The histology of skin preparation shows epidermis, dermis, and subcutaneous fat. The epidermis consists of squamous epithelial cell that appears hyperkeratosis, parakeratosis, and pseudoepitheliomatous hyperplasia. The dermis consists of sebaceous glands, hair follicles, blood vessels, and stroma infiltrated by inflammatory cells. Nodular skin tissue was seen to consist of the epidermis, dermis,

and subcutaneous fat. The dermis shows hyperkeratosis, parakeratosis, and inverted patterns into the dermis. Mild dysplasia and focal focus of koilocytic atypia cells. In the stroma of the dermis, lymphoplasmacytic inflammatory cells were seen. The malignant cell was not seen. Morphologically consistent with Bowenoid Papulosis.



**Figure 2.** Hyperkeratosis (black arrow), parakeratosis (white arrow), mild dysplasia (blue arrow), koilocytic atypia cells (red arrow).

## DISCUSSION

Bowenoid Papulosis (BP) is a rare disease caused by Human Papilloma Virus. Kopf and Bart first described this disease in

1977. HPV types that were identified as the cause of BP are types 16, 18, 31, 33, 34, 35, 39, 42, 53, 54, and 55, but HPV 16 is regarded as the main cause, and HPV 16, 18, and 33 is



considered as oncogenic HPV types related to malignancy or progression to carcinoma *in situ* in BP. Bowenoid Papulosis can appear at any age and especially happened in sexually active individuals in the third to a mid-fifth decade of life.<sup>2,4,5</sup>

The course of Bowenoid Papulosis can range from a few weeks to more than ten years, with an average of 8 months. This disease mainly affects sexually active adults with the majority of female. The lesion commonly seen in genital region, but extragenital lesions can also be affected, such as cases that have been reported in the oral cavity. In male, lesions commonly seen in penile shaft, glans, and foreskin area. In contrast, on female, this disease appears in labia minor, labia major, clitoris, inguinal folds, and perianal.<sup>3,6,7</sup>

This paper reported a 39-years-old male patient with warts over the scrotum and left groin of one-year duration. The patient has a history of the same complaint and cauterization has been done a year ago. Currently the warts are gradually increased in number and size. The identity and chief complaint of the patient in accordance with the characteristics of Bowenoid Papulosis.

Bowenoid Papulosis lesions appear generally as papules or plaques with usual size less than 1 cm and sometimes macular in shape. The lesion has a flat surface, dome-shaped, papillomatous, and verrucous. Color varies from shiny flesh-colored, pink, reddish-brown, black, violaceous, or coloration similar to the surrounding skin or mucosa. Discrete, annular, or linear structures.<sup>6</sup> Most patients present with no symptoms, but some experience itching or mild pain.<sup>8</sup> However, Bowenoid Papulosis is sometimes difficult to distinguish from Condyloma Acuminata due to its similar clinical manifestations.<sup>9</sup>

On dermatological examination of the patient's lesions showed there were multiple, small, well-defined, grey-brown papules on the scrotum and left groin. From the dermatology examination, diagnosis of BP cannot be established. This is due to the

similarity of morphology appearance with Condyloma Acuminata.

Bowenoid Papulosis resembles Condyloma Acuminata due to its similar clinical morphology, size, clinical distribution and short-term evaluation. However, Condyloma Acuminata is caused by HPV 6 and 11. This HPV types does not cause BP. HPV 6 and 11 has low risk of malignancy, and are characterized by flesh, red, or brown color, solitary or confluent, with smooth surface or warty papules. In addition, Condyloma Acuminata has a different histopathological appearance from BP. From the histopathological examination of Condyloma Acuminata, acanthosis, parakeratotic, papillomatous and koilocytes will be found.

Dermoscopy can be useful in ruling out the differential diagnosis because BP lesions resemble genital warts.<sup>5</sup> Dermoscopy examination in BP revealed brown-grey dots in a linear arrangement with dotted vessels. However, these features are also found in Pigmented Bowen's Disease and Cutaneous SCC (cSCC) *in situ*, and need to be distinguished by histopathological examination.<sup>10,11,12</sup>

From dermoscopy examination in this patient, we found pigmented papillomatous surface, brown-grey dots with linear structure at the edges, and widespread dotted vessels. Previous studies reported a similar finding in dermoscopy examination.

Considering the oncogenic potential in BP, biopsies must be taken from lesions which does not heal with standard therapy. Histopathological features of BP represent psoriasiform epidermal hyperplasia, hyperkeratosis with focal parakeratosis, and focal acanthosis with almost full-thickness epidermal atypia (which characterized by hyperchromatic nuclei, prominent nucleoli, mitotic figures, dyskeratotic cells, multinucleated giant cells, and hyperchromatic nuclei) spongiosis and exocytosis. Dermis shows dilated and tortuous capillaries with lymphohistiocytic infiltrate. Epidermal atypia extension, atypia severity, and koilocytes characteristics are

important in the diagnosis of BP from histopathological examination.<sup>3,8</sup>

Finally, an excisional biopsy for large and clustered lesions was performed on this patient, and a histopathological examination was performed. The histology of skin preparation in this patient shows epidermis, dermis, and subcutaneous fat. The epidermis consists of squamous epithelial cells that appear hyperkeratotic, parakeratotic, and pseudo epitheliomatous hyperplasia. The dermis consists of sebaceous glands, hair follicles, blood vessels, and stroma infiltrated by inflammatory cells. Nodular skin tissue was seen to consist of the epidermis, dermis, and subcutaneous fat. The dermis shows hyperkeratotic, parakeratotic, and inverted patterns into the dermis. Mild dysplasia is the cells' focal focus of atypia koilocytes cells. In the stroma of the dermis, lymphoplasmacytic inflammatory cells were seen. The malignant cell was not seen. Morphologically consistent with Bowenoid Papulosis. From this examination, the results were found to be in accordance with BP, so a diagnosis can be made.

Recommended treatment modalities such as surgical excision, electrocoagulation, cryotherapy, CO<sub>2</sub> laser therapy, and photodynamic therapy are not always completely successful due to the multifocal distribution of BP. Other treatment modalities including chemotherapeutics with 5-fluorouracil, podophyllin, cidofovir, imiquimod, and systemic or local retinoids can be chosen.<sup>13</sup>

The development of BP is unpredictable because lesions can expand, diminish, and disappear spontaneously. Nevertheless, special attention must be taken because BP can progress to invasive SCC. Although this is rare, 2.6% of cases have been reported.<sup>7,14</sup> Lesion with longer duration, predominantly in elderly individuals, should be considered a sign of malignant transformation, surgically or laser should be done to remove the lesion. Prevention is necessary, because this STD has been shown to be associated with cervical neoplasia resulting from HPV 16. An important factor is to explain HPV infection

and the importance of using condoms during sexual intercourse. Routine examinations for recurrence should be performed. There is risk of developing cervical cancer in male sexual partners with BP. Therefore, cytologic, colposcopy, and histological examinations should be done as a routine follow up.<sup>3</sup>

In this case, surgical excision had been done. Cauterization has also been performed for small lesions according to the patient's request. Surgical excision is chosen because it is one of the recommended treatment modalities. We also emphasize the importance of using condoms during sexual intercourse, examination of the sexual partner, and routine examinations for recurrence should be performed. Six months after the procedure, the patient had no complaints or new lesions.

## CONCLUSION

Bowenoid papulosis (BP) is generally benign and regresses spontaneously within months, but some cases have reported persistent occurrence. Even though caused by different types of HPV, BP and Condyloma Acuminata has similar clinical morphology, size, clinical distribution and short-term evaluation. Histopathological examination must be performed to confirm diagnosis. BP has a potential malignant transformation. Therefore, appropriate early diagnosis followed by adequate treatment is required. Explanation about HPV infection and the importance of using condoms during sexual intercourse is mandatory. Routine examinations for recurrence should be performed, and special attention must be taken because BP can progress to invasive SCC.

## ETHICS IN PUBLICATION

The patient approved clinical finding documentation and publication.

## AUTHORS CONTRIBUTION

All authors have contributed from patient examination, treatment, follow-up,

reference finding, manuscript preparation, and publication.

## REFERENCES

1. Rimmalapudi, S., Jawade, S., Madke, B., & Singh, A. L. Response of Bowenoid Papulosis to Combination Treatment of Oral Isotretinoin and Topical 1% 5-Fluorouracil. *Journal of Evolution of Medical and Dental Sciences*. 2021;10(35):3067–3069. <https://doi.org/10.14260/jemds/2021/625>
2. Ambooken, B., Asokan, N., Philip, P., & Jisha, K. T. Bowenoid papulosis unveiling a rare cause of immunosuppression. *International Journal of STD and AIDS*. 2019;30(5):522–525. <https://doi.org/10.1177/0956462418813057>
3. Shivanna, R., Kapoor, M., Murthy, Bn., & Narendra, G. (2018). Bowenoid papulosis of genitalia responding to topical 5-Fluorouracil. *Clinical Dermatology Review*. 2018;2(1):25–27. [https://doi.org/10.4103/cdr.cdr\\_11\\_17](https://doi.org/10.4103/cdr.cdr_11_17)
4. Nayak, S. U., Shenoi, S.D., Bhat, S.T., Shi-vamurthy A. Bowenoid Papulosis. *Indian Journal of Sexually Transmitted Disease and AIDS*. 2015;36(2):223–225. <https://doi.org/10.4103/0253-7184.167196>
5. Wahyu, Y., Murtiastutik, D., & Mustokoweni, S. (n.d.). Peranan Human Papillomavirus terhadap Bowenoid Papulosis (The Role of Human Papillomavirus in Bowenoid Papulosis).
6. Peng, W. S., & Tan, C. (2016). Bowenoid papulosis in a linear distribution. *Postepy Dermatologii i Alergologii*. 2016;33(2):146–148. <https://doi.org/10.5114/ada.2016.59161>
7. Ferreira, J. C. B., de Paula, H. M., Caixeta, G. N., & Mendonça, E. F. Distinguishing bowenoid papulosis from Bowen disease in the mouth: A case report. *Journal of Cutaneous Pathology*. 2020;47(3):257–262. <https://doi.org/10.1111/cup.13579>
8. Chan, S. L., Watchorn, R. E., Panagou, E., Panou, E., Ong, E. L. H., Heelan, K., Haider, A., Freeman, A., & Bunker, C. B. Dermatoscopic findings of penile intraepithelial neoplasia: Bowenoid papulosis, Bowen disease and erythroplasia of Queyrat. *Australasian Journal of Dermatology*. 2019;60(3), e201–e207. <https://doi.org/10.1111/ajd.12981>
9. Shimizu, A., Kato, M., & Ishikawa, O. Bowenoid papulosis successfully treated with imiquimod 5% cream. *Journal of Dermatology*. 2014;41(6):545–546. <https://doi.org/10.1111/1346-8138.12510>
10. Guo, J., Chang, J. M., & Liu, W. Bowenoid Papulosis. *International Journal of Dermatology and Venereology*. 2021;3(1):58–59. <https://doi.org/10.1097/JD9.0000000000000066>
11. Marcucci, C., Cohen Sabban, E., Friedman, P., Peralta, R., Calb, I., & Cabo, H. (2014). Dermoscopic findings in bowenoid papulosis: report of two cases. *Dermatology Practical & Conceptual*. 2014;4(5):61–63. <https://doi.org/10.5826/dpc.0404a11>
12. McCalmont, T. H. Whither bowenoid papulosis? *Journal of Cutaneous Pathology*. 2013;40(2):209–210. <https://doi.org/10.1111/cup.12083>
13. Campione, E., Centonze, C., Diluvio, L., Orlandi, A., Cipriani, C., Stefani, A. di, Piccione, E., Chimenti, S., & Bianchi, L. (2013). Bowenoid papulosis and invasive Bowen's disease: A multidisciplinary approach. *Acta Dermato-Venereologica*. 2013;93(2):228–229. <https://doi.org/10.2340/00015555-1328>
14. Lee, H. J., Shin, D. H., Choi, J. S., & Kim, K. H. A case of isolated bowenoid papulosis of the nipple. *Annals of Dermatology*. 2014;26(3):381–384. <https://doi.org/10.5021/ad.2014.26.3.381>

# phinari turnitin result 24.06.2022

## ORIGINALITY REPORT

17%

SIMILARITY INDEX

13%

INTERNET SOURCES

8%

PUBLICATIONS

6%

STUDENT PAPERS

## PRIMARY SOURCES

1	Submitted to Universitas Indonesia Student Paper	4%
2	cdriadvlkn.org Internet Source	2%
3	ejournal.upnvj.ac.id Internet Source	2%
4	medicaljournals.se Internet Source	1%
5	Su - Lin Chan, Richard Edward Watchorn, Evangelia Panagou, Evdoxia Panou et al. "Dermatoscopic findings of penile intraepithelial neoplasia: Bowenoid papulosis, Bowen disease and erythroplasia of Queyrat", Australasian Journal of Dermatology, 2018 Publication	1%
6	www.ncbi.nlm.nih.gov Internet Source	1%
7	Daniel R. Nemirovsky, Rohan Singh, Aria Jalalian, Rena D. Malik. "Urologic dermatology: a comprehensive foray into the noninfectious	1%



# etiologies of balanitis", International Journal of Dermatology, 2021

Publication

8	Submitted to Udayana University Student Paper	1 %
9	<a href="https://synapse.koreamed.org">synapse.koreamed.org</a> Internet Source	1 %
10	<a href="https://e-ijd.org">e-ijd.org</a> Internet Source	<1 %
11	<a href="https://ijstd.org">ijstd.org</a> Internet Source	<1 %
12	<a href="https://journals.lww.com">journals.lww.com</a> Internet Source	<1 %
13	<a href="https://repository.unair.ac.id">repository.unair.ac.id</a> Internet Source	<1 %
14	"Atlas of Dermatology, Dermatopathology and Venereology", Springer Science and Business Media LLC, 2022 Publication	<1 %
15	<a href="https://mts.intechopen.com">mts.intechopen.com</a> Internet Source	<1 %

Exclude quotes On

Exclude matches Off

Exclude bibliography On