

# estu dkk turnitin result

*by* Estu Final

---

**Submission date:** 15-Jun-2022 01:52PM (UTC+0700)

**Submission ID:** 1857178950

**File name:** estu\_dkk\_revision\_15.06.2022.docx (1.43M)

**Word count:** 3540

**Character count:** 19666

## PROFILE OF UNILATERAL CATARACT IN CHILDREN WITH CONGENITAL RUBELLA SYNDROME

Dian Estu Yulia<sup>1\*</sup>, Intan Datya Kirana<sup>1</sup>, Diajeng Ayesha Soeharto<sup>1</sup>

<sup>1</sup> Department of Ophthalmology, Medical School, University of Indonesia

\*Correspondence email: dianestu.dianestu@gmail.com

### ABSTRACT

A congenital cataract is preventable blindness in children and is associated with intrauterine rubella infection known as congenital rubella syndrome (CRS), mostly found in developing countries. This study aims to describe the profile of unilateral cataracts in children with CRS, which are more difficult to manage than bilateral ones. As a retrospective study, we reviewed complete medical records of children with CRS and unilateral cataracts at Cipto Mangunkusumo hospital from 2017 to 2020. Fifteen patients were included, mostly male and from outside Jakarta. The mean age of onset was 2.9 months, while the average age at first presentation and surgery was 27.7 months and 29.1 months, respectively. No correlation was found between patients' residential distance from the hospital towards duration between onset of symptoms and first presentation to the hospital. 100% and 66.7% of patients had leukocoria and microcornea as ocular manifestations. The majority of systemic manifestations are congenital heart disease. 66.7% of children underwent cataract surgery without IOL implantation. Improvement of visual acuity postoperatively was observed in 13.3% of patients, and 66.7% of patients used contact lenses for visual rehabilitation. 60% of patients had posterior capsule opacity within six months of follow-up. The challenge of wearing contact lenses in children makes the risk of amblyopia even greater.

**Keywords:** Cataract surgery; Congenital rubella syndrome; Contact lens; Microcornea; Unilateral

### INTRODUCTION

Congenital cataracts are one of the major causes of preventable blindness, affecting 5 to 15 out of every 10,000 children in developing countries.<sup>1,2</sup> One of the major etiologies of congenital cataracts is intrauterine infection, including rubella.<sup>3</sup> Congenital rubella syndrome (CRS) is mainly found in developing countries, and it is estimated that 238,000 children are born with CRS yearly. In India, an estimate of 50,000 children each year are born blind due to congenital cataracts, and at least 25% of cases were caused by rubella.<sup>4</sup>

The classic triad of CRS includes congenital cataracts, sensorineural deafness, and a congenital heart defect.<sup>5,6</sup> Ocular

manifestations related to rubella include glaucoma, microcornea, and retinopathy.<sup>7</sup>

Congenital cataracts can occur unilaterally or bilaterally. Primary treatment includes cataract surgery and is most optimal if conducted as promptly as possible. Birch et al. recommended surgery to be conducted within the first six weeks for unilateral cases and is recommended to be done even sooner in bilateral cases. Delaying surgery can increase the risk of amblyopia, nystagmus, and strabismus.<sup>8</sup>

Following pediatric cataract surgery, optimal visual rehabilitation is of utmost importance, and this can be achieved through intraocular lens (IOL) implantation, contact lenses, or glasses.<sup>9</sup> However, unilateral cataracts can

only rely on the first two options. Contact lens use in children itself serves as a challenge and is more difficult in CRS patients with a developmental delay that further complicates compliance. Furthermore, contact lenses are relatively more expensive as Indonesia's national health coverage does not cover them.

Complications following cataract surgery in children include posterior capsule opacity (PCO), which can further deteriorate visual acuity; thus, it is important to monitor patients postoperatively closely. Moreover, comprehensive treatment by related fields is essential in CSR patients with ocular and systemic manifestation.<sup>10,11</sup>

## 6 MATERIAL AND METHODS

A retrospective review was conducted on the medical records of all patients with congenital rubella syndrome who underwent unilateral cataract surgery<sup>25</sup> at the Department of Ophthalmology, Cipto Mangunkusumo National Central General Hospital, Jakarta, Indonesia. Data collected was from the 1<sup>st</sup> of January 2017 to the 3<sup>rd</sup> of December 2020. Patients included had a minimum follow-up period of 6 months postoperatively. Extracted data included the following: demographic data, including place of residence, gender, age of onset, age at presentation to hospital, age at surgery, as well as ocular and systemic manifestations, visual acuity, type of cataract surgery, complications, and choice of postoperative visual rehabilitation.

Descriptive analysis was done on the characteristics of the subjects, and quantitative data were described as mean (SD) or median (min-max). Categorical variables were presented in frequency, and percentage, n (%), was used. Spearman analyzed the association between distance from the place of residence and interval between symptom onset and presentation to the hospital. Data was inserted into Microsoft Office Excel v 16.48 and then analyzed using IBM SPSS (Statistical Package for the Social Sciences) version 26.

## RESULT

Our data retrieval process resulted in 18 patients with CRS who underwent unilateral cataract surgery. However, three patients were excluded due to incomplete medical records. This resulted in a total of 15 patients included in this study for analysis (see Figure 1).

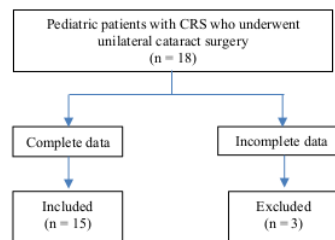


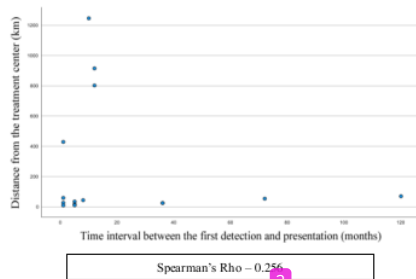
Figure 1. Data collection flowchart

As shown in Table 1, 86.7% of patients resided outside of Jakarta. The majority (60%) of patients were male. Average age of symptom onset was  $2.9 \pm 4.0$  months of age, with a range of 0-12 months of age. Cataract surgery was performed at an average of  $29.1 \pm 34.8$  months of age, and ranged from 3-131 months of age.

**Table 1.** Demographic data of patients, n = 15

Variable	n (%)	Mean ± SD (range)
Residence		
Jakarta	2 (13.3)	
Outside Jakarta	13 (86.7)	
Gender		
Male	9 (60)	
Female	6 (40)	
Age of Onset (months)		2.93 ± 4.00 (0-12)
Age at Presentation to Hospital (months)		27.73 ± 34.33 (1-130)
Age at surgery (months)		29.10 ± 34.81 (3-131)

In order to explore distance from hospital as a potential factor in delay to treatment, we assess the correlation between patient distance from hospital and time interval between symptom on onset and first presentation to hospital. Figure 2 shows that patients who resided in Jakarta as well as outside of Jakarta varied greatly in terms of distance from the hospital, ranging from 9 to 246 km. Analysis showed very weak correlation (Spearman's correlation coefficient = 0.256) between distance from hospital towards delay in treatment.



**Figure 2.** Correlation of time interval between the first detection and presentation (months) vs distance from the treatment center (kilometers)

The most common ocular manifestation in the patients included in this study was leukocoria (see Table 2).

**Table 2.** Ocular Manifestation

Ocular Manifestation	Number of patients, n (%)
Cornea ≤ 9 mm (microcornea)	10 (66.7)
Leukocoria	15 (100)
Retinopathy	3 (20)

The most common systemic manifestation in the patients in our study was congenital heart disease (73.3%), followed by hearing loss (66.7%). All patients had more than one systemic manifestation (see Table 3).

**Table 3.** Systemic Manifestation

Systemic manifestation	Number of patients, n (%)
Congenital Heart Disease	11 (73.3)
Hearing loss	10 (66.7)
Microcephaly	7 (46.7)
Global delayed development	5 (33.3)

Table 4 shows that 66.7% of patients had cataract extraction without an IOL implant. These were due to microcornea (cornea ≤ 9 mm), which serves as a contraindication for IOL implantation.

**Table 4.** Type of cataract surgery

Surgery	Number of patients, n (%)
Cataract extraction with IOL implant	5 (33.3)
Cataract extraction without IOL implant	10 (66.7)

The majority of pre-operative visual acuity could not be evaluated due to the children's inability to cooperate during the examination. Postoperatively, improved visual acuity was observed in two patients in terms of improvement from light fixation to object fixation. However, most patients had unchanged visual acuity, 40% of which had following objects and hand movement (shown in Table 5).

**Table 5.** Distribution of visual acuity

	Pre-operative Number of patients, n (%)	Postoperative Number of patients, n (%)
Light fixation (+)	2 (13.3)	0 (0)
Following objects (+)	5 (33.3)	7 (46.7)
Hand movement	1 (6.7)	1 (6.7)
Unable to be examined	7 (46.7)	7 (46.7)

The majority of patients used contact lenses as their choice for visual rehabilitation, this was due to most of the patients having microcornea, which is a contraindication for IOL implantation (see Table 6).

**Table 6.** Visual rehabilitation

Type	Number of patients, n(%)
Contact lens	10 (66.7)
IOL	5 (33.3)

Nine patients (60%) were reported to have PCO as a postoperative complication. However, from all PCO cases, none were reported to have visual axis opacification (VAO) six months following surgery

**Table 7.** Complication

Complication (n = 15)	Number of patients, n (%)
PCO	9 (60.0)
VAO (-)	15 (100.0)

PCO = Posterior capsule opacification, VAO = Visual axis opacification

## DISCUSSION

Congenital cataracts can happen at any stage at the beginning of life. Chen et al. stated that up to 80% of unilateral congenital cataracts in their study consisted of males, while 20% were females.<sup>12</sup> This is in line with the findings of our study. There were predominantly males and accounted for 60% of our study population. Lindbald et al., on the other hand, reported similar proportions between genders in which 53% of their population were male and 47% were female.<sup>13</sup> In this study, rubella cataract was

congenital. Thus gender differences may not be apparent.

Cataracts in CRS maybe be unilateral or bilateral. Most unilateral cataracts in CRS had an onset of below six months of age (46.7%), followed by below one month of age (40.0%). This is in accordance with the pathogenesis of CRS, in which the virus is transmitted through maternal vasculature during pregnancy. The fetus is prone to infection due to the lack of specific immunity against the virus that has not been formed within the first two trimesters, and infection at this stage of life where the fetus is undergoing organogenesis can have detrimental outcomes. Infection during lens development results in lens fiber degeneration and failure of the lens dehydration process, leading to lens opacification.<sup>14-16</sup> This explains how cataract in children with CRS tends to have an onset that is earlier in life. With this, children with leukocoria should be promptly taken to a health care facility for further examination.

A study by Li et al. in China stated that cataract surgery in children ages 3-15 months of age resulted in good visual outcomes in terms of visual acuity.<sup>17</sup> Moreover, Birch et al. recommended unilateral cataract extraction surgery should be done before six weeks of age. In contrast, other studies stated 2-8 weeks of age as the optimal period for cataract extraction.<sup>12,18</sup> In this study, the average age at surgery was 29.1 months. Delay in the age of surgery in this study may be attributed to delay in presentation to the hospital, in which the average age at which patients first visit our hospital was 27.73 months. Other factors may include a lack of parent or caregiver awareness regarding their children's vision problems leading to delays in seeking care.

Distance from a place of residence to our hospital potentially serves as one of the factors in delay of care, as lack of access in terms of transport to healthcare facilities as well as financial barriers can inhibit caregivers from seeking appropriate care as soon as possible. In this study, we attempted to evaluate the correlation between distance and time interval from

symptom onset to first presentation to the hospital, and we found a very weak correlation between the two factors ( $p = 0.256$ ). In contrast, Sudarshan et al. reported a strong correlation between distance and delay in treatment.<sup>19</sup> The lack of correlation in our study, despite our patients' residence being relatively far, may be due to our hospital being accessible via land transport.

Ocular manifestations of cataracts are often found in patients with CRS. In this study, all of our patient's chief complaints at presentation were leukocoria. Vijayalakshmi et al.'s study in India explained that cataracts are highly related to CRS in patients with visual problems.<sup>20</sup> Givens et al. explained that 27% of CRS patients had cataracts, and 10% of patients had unilateral cataracts.<sup>15</sup>

Furthermore, in this study, microcornea, a condition in which diameter of the cornea is ( $< 9$  mm), was found in 66.7% of patients. Similar findings were reported by Vijayalakshmi et al. in India, who also reported a significant connection between microcornea and CRS.<sup>20</sup> Microcornea occurs due to failure of eye development due to delayed development from rubella infection.<sup>15</sup>

Other ocular manifestations in this study include retinopathy pigmentary, which was found in 20% of patients. The reported rate of retinopathy pigmentary in CRS varies greatly. For instance, Vijayalakshmi et al., Givens et al., and Rajasundari et al. reported 37.9%, 60%, and 11.1% of cases with retinopathy, respectively.<sup>4,15,21</sup> In this study, the low rate of retinopathy pigmentary may be due to a lack of patient cooperation leading to difficulty in performing fundus examination in the outpatient clinic setting.

Glaucoma may also serve as a common finding in CRS. This is due to trabeculodysgenesis from persistent rubella infection of the trabecular tissues. Failure of the canal of Schlemm to differentiate during the period of development may also lead to glaucoma.<sup>14,22</sup> Rajasundari et al. reported

11% of CRS patients had glaucoma.<sup>21</sup> Our study was unable to report on intraocular pressure in our patients due to a lack of cooperation during the examination. Thus, routine postoperative follow-up is essential.

In general, reported rates of systemic manifestation in CRS include 60% with hearing loss, 45% with congenital heart defects, and 27% with microcephaly.<sup>17</sup> Givens et al. mentioned in their study that in CRS patients with vision problems, 62% had congenital heart defects, and 53% had hearing loss.<sup>15</sup> This is in line with our study's findings that found the majority of patients with a congenital heart defect and hearing loss. CRS should be evaluated in patients with the classic triad of CRS, including a congenital heart defect, hearing loss, and visual problems in neonates and children.

Cataract extraction with an IOL implant was done in five patients, while ten underwent cataract extraction without an IOL implant. Patients who did not have IOL implanted were patients with microcornea, as microcornea serves as a contraindication for IOL implant.<sup>8</sup> IOL implantation in patients with a corneal diameter of 9 mm has a narrow anterior chamber depth, which can lead to difficulty in implanting the IOL and increase the risk of cornea endothelial dysfunction.<sup>23</sup>

The average age at presentation to our hospital is 27.7 months, and surgery was performed at an average of 29.1 months of age, which shows that the duration between patient presentation to surgery was relatively prompt in our study. Despite this, we only observed improved visual acuity of 13.3%, where patients' visual acuity improved from light fixation preoperatively to following objects postoperatively. In 40% of patients who had unchanged visual acuity after surgery, their visual acuity remained at either following objects or hand movement. Visual acuity of the affected eye in nearly half of our patients could not be evaluated due to a lack of patient cooperation during an examination. Unchanged visual acuity after surgery in

this study may be due to the age at which patients were brought to the hospital, where the average age of presentation was 27.73 months. Meanwhile, symptom onset was, on average, 2.93 months. This delay in seeking treatment despite the early onset of symptoms elevates the risk of amblyopia. Visual deprivation due to unilateral cataracts has an inherent risk of amblyopia in comparison to that of bilateral cataracts.<sup>24</sup>

In our study, 33.3% of patients had cataract surgery with IOL implantation as the choice for visual rehabilitation, while the majority (66.7%) that did not receive IOL implantation used contact lenses as the choice for visual rehabilitation. The high rate of contact lens use in unilateral cataract CRS patients after surgery serves as a challenge in itself, as most patients are children with delayed development. Thus, the process of measurement requires anesthesia due to their lack of cooperation. Moreover, contact lenses are relatively costly and not covered by national health insurance. With this, close collaboration between healthcare providers and caregivers in these cases is needed due to the risk of amblyopia and strabismus.<sup>22</sup>

PCO is one of the most common postoperative complications in pediatric cataract surgery.<sup>10,11</sup> Proper wound healing of lens epithelial cells post-cataract surgery is the key to preventing PCO. Inflammation-induced by suture removal and removal of lens cells are also influential. PCO<sup>19</sup> is most often found in younger children due to the amount of lens epithelial cells in the capsular pocket with greater proliferation potential and reactive uveas at this age which ease membrane formation as a result of the postoperative inflammation process. In this study, 60% of the patients were reported to have PCO. However, their visual axis was found to be clear six months after surgery, with the average age at surgery of 29.1 months.<sup>25,26</sup> Thus far, there is no data regarding rubella as the cause of infection that can initiate PCO occurrence.

## CONCLUSION

Cataract surgery without IOL implantation was the main treatment in children with unilateral cataracts and CRS, and contact lenses were the only optical aid for visual rehabilitation.<sup>11</sup> Because of the inherent challenge of contact lens wear in children, the risk of amblyopia is higher in unilateral cataracts than in bilateral cataracts.

The limitation of this study is the incomplete medical records in the hospital. Larger subjects of unilateral cataracts in children with CRS may be needed for further study.

## REFERENCES

1. Khokhar S, Jose CP, Sihota R, Midha N. Unilateral congenital cataract: Clinical profile and presentation. *Journal of Pediatric Ophthalmology and Strabismus*. 2018;55(2):107–12.
2. Shah MA, Shah SM, Shah AH, Pandya JS, Netralaya D. Visual outcome of cataract in pediatric age group: Does etiology have a role? *European Journal of Ophthalmology*. 2013;24(1):76–83.
3. Shah SK, Praveen MR, Vasavada AR, Vasavada VA, Carelli R, Trivedi RH, et al. Long-term longitudinal assessment of postoperative outcomes after congenital cataract surgery in children with congenital rubella syndrome. *Journal of Cataract and Refractive Surgery*. 2014;40(12):2091–8.
4. Vijayalakshmi P, Gaurav K, Samprathi A, Banushree R. Ocular Manifestations of Congenital Rubella Syndrome in a Developing C. 2002.
5. Nazme NI, Hussain M, Das AC. Congenital Rubella Syndrome-A Major Review and Update. *Vol. 3, Delta Med Col J. Jul. 2015*.
6. Atreya CD, Mohan KVK, Kulkarni S. Rubella virus and birth defects: Molecular insights into the viral teratogenesis at the cellular level. *Vol. 70, Birth Defects Research Part A - Clinical and Molecular Teratology*. 2004. p. 431–437.

Commented [T1]: Nama jurnal.2015;Vol(No):.....



7. Givens KT, Lee DA, Jones T, Ilstrup DM, Stein J. Congenital rubella syndrome: ophthalmic manifestations and associated systemic disorders [Internet]. Vol. 77, *British Journal of Ophthalmology*. 1993. Available from: <http://bjo.bmj.com/>
8. Koo EB, Gilbert AL, VanderVeen DK. Treatment of Amblyopia and Amblyopia Risk Factors Based on Current Evidence. *Seminars in Ophthalmology*. 2017;32(1):1–7.
9. Mohammadpour M, Shaabani A, Sahraian A, Momenaei B, Tayebi F, Bayat R, et al. Updates on managements of pediatric cataract. Vol. 31, *Journal of Current Ophthalmology*. 2019;31:118–126.
10. Retno LW, Radika Laboratorium Ilmu Kesehatan Mata Rumah Sakit Umum Saiful Anwar Malang KH. Katarak Pediatrik: Profil Klinik dan Faktor Determinan Hasil Terapi Pediatric Cataract: Clinical Profile and Outcomes *Determinant*.
11. Long J, Xiang D, Guo Z, Chen L, Chen F, Wang J, et al. Clinical Characteristics and Surgical Procedures for Children with Congenital Membranous Cataract. *Journal of Ophthalmology*. 2017;2017.
12. Chen YCE, Hu AC, Rosenbaum A, Spooner S, Weissman BA. Long-term results of early contact lens use in pediatric unilateral aphakia. *Eye and Contact Lens*. 2010;36(1):19–25.
13. A Randomized Clinical Trial Comparing Contact Lens With Intraocular Lens Correction of Monocular Aphakia During Infancy Grating Acuity and Adverse Events at Age 1 Year The Infant Aphakia Treatment Study Group\* [Internet]. Available from: <http://www.sphemory/>
14. Vijayalakshmi et al. Ocular Manifestations of Congenital Rubella Syndrome 307 Ocular Manifestations of Congenital Rubella Syndrome in a Developing Country. 2002
15. Givens KT, Lee DA, Jones T, Ilstrup DM, Stein J. Congenital rubella syndrome: ophthalmic manifestations and associated systemic disorders [Internet]. Vol. 77, *British Journal of Ophthalmology*. 1993. Available from: <http://bjo.bmj.com/>
16. Duszak RS. Congenital rubella syndrome-major review. *Optometry*. 2009;80:36–43.
17. Li L, Wang Y, Xue C. Effect of timing of initial cataract surgery, compliance to amblyopia therapy on outcomes of secondary intraocular lens implantation in Chinese children: A retrospective case series. *Journal of Ophthalmology*. 2018;
18. Vishwanath M, Cheong-Leen R, Taylor D, Russell-Eggitt I, Rahi J. Is early surgery for congenital cataract a risk factor for glaucoma? *British Journal of Ophthalmology*. 2004;88:905–910.
19. Magnusson G, Haargaard B, Basit S, Lundvall A, Nyström A, Rosensvård A, et al. The Paediatric Cataract Register (PECARE): an overview of operated childhood cataract in Sweden and Denmark. *Acta Ophthalmologica*. 2018;96(1):51–55.
20. Vijayalakshmi P, Rajasundari TA, Prasad NM, Prakash SK, Narendran K, Ravindran M, et al. Prevalence of eye signs in congenital rubella syndrome in South India: A role for population screening. *British Journal of Ophthalmology*. 2007;91(11):1467–1470.
21. Rajasundari TA, Sundaresan P, Vijayalakshmi P, Brown DWG, Jin L. Laboratory confirmation of congenital rubella syndrome in infants: An eye hospital based investigation. *Journal of Medical Virology*. 2008;80(3):536–546.
22. Mohammadpour M, Shaabani A, Sahraian A, Momenaei B, Tayebi F, Bayat R, et al. Updates on managements of pediatric cataract. *Journal of Current Ophthalmology*. Iranian Society of Ophthalmology; 2019;31:118–126.
23. Yu YS, Lee JH, Chang BL. Surgical management of congenital cataract associated with severe microphthalmos. 2000.
24. Repka MX. Visual rehabilitation in pediatric aphakia. *Developments in Ophthalmology*. 2016;57:49–68.

**Commented [T2]:** Nama jurnal.1993;Vol(No):.....  
Tahun penerbitan terlalu tua . Mohon diganti , referensi 10 tahun terakhir

**Commented [T9]:** Vol(No):.....

**Commented [T3]:** Nama author ditulis semua

**Commented [T10]:** Nama author ditulis semua

**Commented [T4]:** Tahun penerbitan dan jumlah halaman  
Ini apa? Majalah atau apa?

**Commented [T5]:** Nama author ditulis semua

**Commented [T11]:** Author ditulis semua

**Commented [T12]:** Author ditulis semua

**Commented [T6]:** Kapan ditarik dari internet, dituliskan

**Commented [T7]:** Ini apa? Jurnal atau buku?

**Commented [T13]:** Jumlah halaman?

**Commented [T8]:** Sama dengan no 7. Harap dihapus



25. Cooksley G, Lacey J, Dymond MK, Sandeman S. Factors affecting posterior capsule opacification in the development of intraocular lens materials. *Pharmaceutics*. MDPI; 2021;13:13.
26. Boengas S. Profil Kekeruhan Kapsul Lensa Posterior Pasca-Operasi Katarak Developmental. *KELUWIH: Jurnal Kesehatan dan Kedokteran*. 2020;1(2):53–61.

**Commented [T14]:** Vol(No):.....  
Harap lengkapi

# estu dkk turnitin result

## ORIGINALITY REPORT

12%

SIMILARITY INDEX

9%

INTERNET SOURCES

7%

PUBLICATIONS

0%

STUDENT PAPERS

## PRIMARY SOURCES

1

[ejournal.upnvj.ac.id](http://ejournal.upnvj.ac.id)

Internet Source

4%

2

Sudarshan Khokhar, Cijin P. Jose, Ramanjit Sihota, Neha Midha. "Unilateral Congenital Cataract: Clinical Profile and Presentation", Journal of Pediatric Ophthalmology & Strabismus, 2018

Publication

1%

3

[www.ncbi.nlm.nih.gov](http://www.ncbi.nlm.nih.gov)

Internet Source

1%

4

Elisabeth Siti Herini, Agung Triono, Kristy Iskandar, Ashadi Prasetyo, Andika Priamas Nugrahanto, Gunadi. "Congenital Rubella Syndrome Surveillance After Measles Rubella Vaccination Introduction in Yogyakarta, Indonesia", Pediatric Infectious Disease Journal, 2021

Publication

1%

5

[worldwidescience.org](http://worldwidescience.org)

Internet Source

1%

6	Paul S. Mueller, Scott M. Albin, Roxann D. Barnes, Keith G. Rasmussen. "Safety of Electroconvulsive Therapy in Patients With Unrepaired Abdominal Aortic Aneurysm", The Journal of ECT, 2009 Publication	<1 %
7	"The Eye in Pediatric Systemic Disease", Springer Science and Business Media LLC, 2017 Publication	<1 %
8	"Pediatric Lens Diseases", Springer Science and Business Media LLC, 2017 Publication	<1 %
9	<a href="http://substanceabusepolicy.biomedcentral.com">substanceabusepolicy.biomedcentral.com</a> Internet Source	<1 %
10	Kleinmann, Guy, Brian Zaugg, David J. Apple, and Jamal Bleik. "Pediatric cataract surgery with hydrophilic acrylic intraocular lens", Journal of American Association for Pediatric Ophthalmology and Strabismus, 2013. Publication	<1 %
11	"Corneal Diseases in Children", Springer Science and Business Media LLC, 2017 Publication	<1 %
12	<a href="http://www.dovepress.com">Www.dovepress.com</a> Internet Source	<1 %

13	Internet Source	<1 %
14	core.ac.uk Internet Source	<1 %
15	journals.plos.org Internet Source	<1 %
16	krepublishers.com Internet Source	<1 %
17	www.ijo.in Internet Source	<1 %
18	www.motherisk.ca Internet Source	<1 %
19	Lens Epithelium and Posterior Capsular Opacification, 2014. Publication	<1 %
20	dokumen.pub Internet Source	<1 %
21	m.scirp.org Internet Source	<1 %
22	pubannotation.org Internet Source	<1 %
23	www.ekjo.org Internet Source	<1 %
24	www.mdpi.com Internet Source	

<1 %

25

[www.science.gov](http://www.science.gov)

Internet Source

<1 %

26

S. R Lambert. "Congenital rubella syndrome: the end is in sight", British Journal of Ophthalmology, 5/15/2007

Publication

<1 %

27

Phoebe D. Lenhart, Scott R. Lambert. "Current management of infantile cataracts", Survey of Ophthalmology, 2022

Publication

<1 %

Exclude quotes On

Exclude matches Off

Exclude bibliography On