

nursalim turnitin result

24.06.2022

by Nursalim Final

Submission date: 24-Jun-2022 01:49PM (UTC+0700)

Submission ID: 1862187993

File name: Nursalim_dkk._revision_062222.docx (523K)

Word count: 2151

Character count: 12633

AMAUROSIS FUGAX PRECEEDING CENTRAL RETINAL ARTERY OCCLUSION: A CASE REPORT

Ade John Nursalim^{1*}, Vera Sumual¹, Andrew Cietra¹, Elbetty Simanjuntak¹, Christian Maramis Komaling¹, Stevanus Josafat Loho¹

¹ Ophthalmology department RSUP Prof dr R D Kandou, Sam Ratulangi University, North Sulawesi Province, Manado City, Indonesia *Correspondence email: dr.adejn@gmail.com

ABSTRACT

Amaurosis fugax is a temporary condition characterized by transient visual loss which lasts several minutes or hours. This symptom can precede central retinal artery occlusion, which can cause permanent visual loss and bear several morbidity and mortality risks. We are reporting a manifestation of a 59-year-old female with an unknown history related to risk factors who developed a vision loss without pain in her right eye after experiencing similar symptoms for a short time. We describe the clinical features and other findings related to the diagnosis and discuss the further risk and management. Medical history, physical examination, and optical coherence tomography diagnosed acute central retinal artery occlusion. This includes a history of painless monocular vision loss, macular cherry-red spots, and papilledema. The diagnosis was confirmed by optical coherence tomography showing hyper reflectivity in the inner retinal layer, retinal edema, and hyper reflectivity in the outer retinal layer. Blood test including complete blood check, erythrocyte sedimentation rate (ESR), C reactive protein (CRP), lipid profile, and inflammatory markers are in normal limit. The patient was then administered to further secondary vascular occlusion prevention, including a blood test, and referred to the neurology department for further examination. Early diagnosis and prompt treatment are necessary for this occlusive disease. A comprehensive examination to mitigate secondary vascular occlusion is needed to prevent morbidity and mortality.

Keywords: Amaurosis fugax, Central retinal artery occlusion

INTRODUCTION

Amaurosis fugax (AF) results from occlusion or stenosis of eye vascularization. This symptom may last minutes or hours.¹ Amaurosis fugax can extend into Central retinal artery occlusion (CRAO), a more serious vascular condition. CRAO is a rare retinal vascular disease estimated to be 1 in 100.000 people.² Von graves first described this disease in 1859 occurred in endocarditis patients.³ Since then, Endocarditis has become the first known risk factor of CRAO. As time passes, other risk factors, including diabetes, heart disease, smoking, hypertension, dyslipidemia, and drug abuse, become known to be related to CRAO.^{1,4,5}

AF is a consequence of internal carotid artery occlusion. This symptom is usually caused by thromboembolism or hypoperfusion.¹ Amaurosis Fugax were seen in 8,5% of all CRAO Patient.⁶ Amaurosis Fugax occurs mostly in a patient over 50 years old, especially if there are vascular risk factors. 2-3% of amaurosis fugax patients bear a risk of hemispheric stroke.¹ CRAO is also associated with myocardial infarction and mortality.⁷

We describe a patient's case who had an experience of amaurosis fugax before later developing to CRAO with monocular vision loss.

CASE PRESENTATION

This patient was a female of minahasa ethnicity, age 59. The patient came with a chief complaint of sudden right eye vision loss seven days ago. The patient didn't feel any pain due to this vision loss. This symptom came suddenly in the morning while the patient woke up. The patient had this symptom for the first time about one month ago, but the Symptoms were resolved suddenly in a few minutes. The patient thought that this second occurrence was the same as the initial. After four days without recovery, she went to the hospital for help. No recent medication or procedure was taken. The patient doesn't have any history of hypertension, valvular disease, hypercoagulability, hyperlipidemia, migraine, non-stroke cerebrovascular disease, diabetes, septicemia, systemic vasculitides, smoking, Transient ischemic attack, endarterectomy procedure, valvular disease, valvular septal procedure, heart, and arteriosclerotic disease.

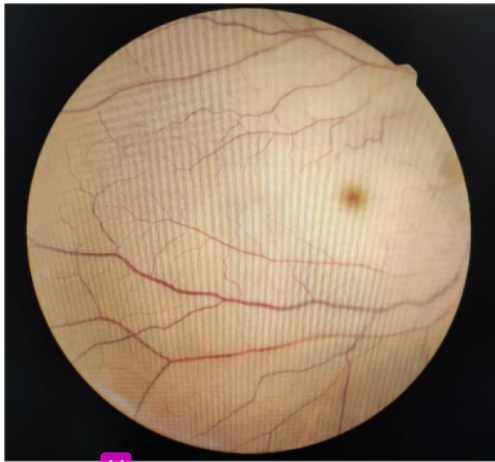

Figure 1. Right eye fundus examination with pale retina and cherry red spot appearance

Physical examination found blood pressure of 125/80 mmHg, with an 84 bpm heart rate. Ocular pressure 11 and 12 in the right and left eyes consecutively. On ophthalmology examination, light perception in the right eye and 20/20 in the left eye were the best-corrected visual acuities. Right eye

examination showed normal fundus with a relative afferent pupillary defect. Fundus examination of the right eye revealed a pale retina. Pale occurred in all fields, including the macula, with peripheral retinal pigment epithelium hyperpigmentation. This appearance made a representation of a Cherry red spot. The examination also revealed loss of physiological foveal reflex and arterial narrowing. The optic disc was swelling. (Figures 1 & 2) A routine fundus exam of the left eye revealed nothing unusual.

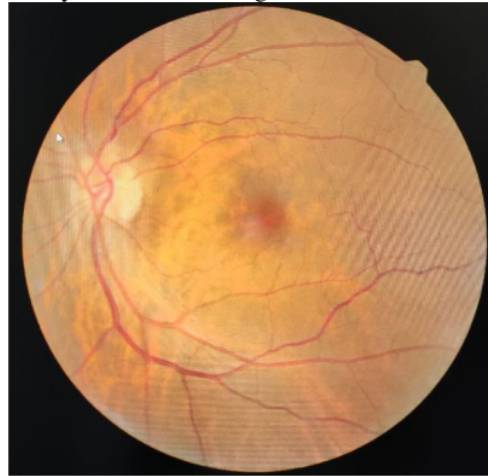


Figure 2. Left Eye fundus examination is unremarkable.

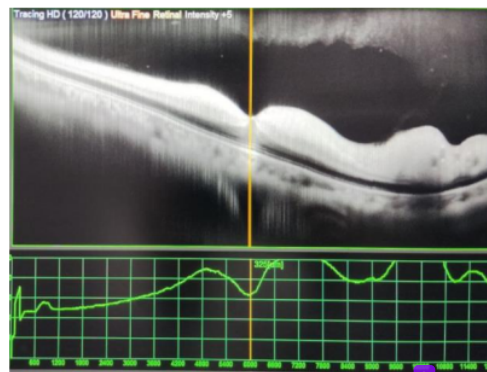


Figure 3. retinal edema was visible on Optical Coherence Tomography examination, and hyperreflectivity of the inner retina with hyporeflectivity of the outer retina layer.

Optical coherence tomography (OCT) depicted retinal edema, hyperreflectivity of the inner and hyporefectivity of the outer retina layer. (Figure 3) Blood test including complete blood check, ESR, CRP, lipid profile, and inflammatory markers within normal limit. The patient was then diagnosed with acute CRAO. The patient was sent to the Neurology department for additional testing and a stroke risk evaluation.

DISCUSSION

AF is experienced as a sudden, temporary, partial, or total vision loss. This symptom lasts a few seconds to several minutes. This symptom should be put into special attention to the medical history. The anamnesis also must uncover the presence of potential risk factors, including circulatory, ocular, and neurologic etiology. The frequency of the Amaurosis fugax determines the most possible cause. Hypoperfusion related to artery stenosis is more likely to be the cause of persistent temporary vision loss than thromboembolism. The increasing frequency of visual loss is typically caused by cerebral infarction.⁸ This patient had this symptom for the second time in one month, so the probable etiology might be hypoperfusion or embolism. The patient is a 59-year-old female. AF in this age is mostly caused by Ischemic etiology. This patient's monocular vision loss is also highly related to the occlusive condition.⁸ Patient doesn't have any history of hypertension, valvular disease, hypercoagulability, hyperlipidemia, migraine, non-stroke cerebrovascular disease, diabetes, septicemia, systemic vasculitis, smoking, Transient ischemic attack, endarterectomy procedure, valvular disease, valvular septal procedure, heart, and arteriosclerotic disease. Age over 50-year-old is a contributing risk factor in developing AF.¹

According to anamnesis assessment, the most likely etiology of this patient's AF is embolism/ischemic. Although not in this patient, some patients, especially with branch artery occlusion with emboli, can be observed thru indirect ophthalmoscopy. Small, yellow, and refractile plaque known as Hollenhorst

plaques formed from cholesterol emboli, a white, non-scintillating plaque at the proximal retinal vasculature from calcific emboli and pale bodies known as fibrinoplatelet can be observed in intraretinal vascular.⁸

AF in this patient has been extended to CRAO. About 12% of CRAO has a preceding symptom of AF.⁹ CRAO is an ocular disease that raises the possibility of permanent vision loss. Mono ocular vision loss with ocular findings in this patient confirm the diagnosis. Fundus examination revealed a Pale retina with a Cherry red spot appearance which is visible in 90% of all patients with CRAO.¹⁰ optical coherence tomography examination represents retinal edema, hyperreflectivity of the inner layer of retina with hyporefectivity of the outer side of retina. These findings depicted an acute stage where macular thickness increased in the acute stage and became reduced after three months of onset.¹¹ This is caused by inflammation in the acute state followed by atrophy in the chronic stage.¹² OCT can be a useful non-invasive diagnostic tool to determine whether CRAO is in an acute or late stage.¹³

The mechanical approach known in CRAO management is ocular massage. This effort basically attempts to dislodge emboli as the cause of CRAO. Nevertheless, this therapy possesses no therapeutical effect to CRAO as well as any popular therapy such as hyperbaric oxygen, global compression, intravenous acetazolamide, anterior chamber paracentesis, sublingual isosorbide dinitrate, systemic pentoxifylline, or inhalation of carbogen. The administration of intravenous tPA gains its popularity recently. However, this therapy also doesn't significantly change vision in acute CRAO below 24-hour onset. However, this therapy improves more than 17% lines within 6 hours of onset.^{4, 10} European Assessment Group for Lysis in the Eye (EAGLE) supports this statement with a multicentre prospective randomized controlled trial. EAGLE found no significant difference between tPa administration and the standard therapy group. Nevertheless, adverse events such as vascular injury, increased stroke risk, longer procedural time, and the

fibrinolysis group also had a higher need for a neurointerventionist, compared to the standard therapy.^{14, 15} considering all of this evidence, none of this therapy has been done to this patient.

The mainstay of therapy for this patient is secondary vascular occlusion prevention. Further occlusion can raise the risk of more devastating organ destruction, including cerebral ischemia, which can lead to stroke and myocardial infarction.⁴ Patients with CRAO need prompt neurologic examination and preventive medicine to prevent mortality.¹⁶ There is an elevated risk of Stroke after CRAO. 25,3% of CRAO patients develop stroke in 1 year.^{17, 18} Dyslipidaemia, hypercoagulability state, and other risk factors need to be investigated. Blood tests and vascular review should be done to prevent fellow eye occlusive disease or systemic ischaemic events.

CONCLUSION

Amaurosis fugax is an important clinical finding of any patient. A systematic approach helps to pinpoint the diagnosis. The evaluation needs to consider Circular, ocular, and neurologic causes of AF. CRAO as an ocular emergency has been considered analog to cerebral stroke and can follow the occurrence of AF. Findings of CRAO increase the risk of brain and cardiovascular disease. Interdisciplinary approaches must be made to mitigate the risk of further medical comorbidities or mortality risk. The first-line target of CRAO management is vascular reperfusion. This effort requires fast and appropriate action. The next step in CRAO management is to prevent secondary vascular occlusion. This can be done thru a comprehensive risk factors assessment. This can be done with interprofessional collaboration.

ACKNOWLEDGMENTS

The authors are thankful for the Management of Prof dr R D Kandou central hospital and Sam Ratulangi University, Manado.

REFERENCES

1. Tadi P, Najem K, Margolin E. Amaurosis fugax. StatPearls [Internet]: StatPearls Publishing; 2021.
2. Rumelt S, Dorenboim Y, Rehany U. Aggressive systematic treatment for central retinal artery occlusion. *American journal of ophthalmology*. 1999;128(6):733-738.
3. Flores JP, Blanco GE, Rivas MP, Montero M, Breyse MM, Lluva ML. Central retinal artery occlusion and infective endocarditis: Rigor does matter. *Archivos de la Sociedad Española de Oftalmología (English Edition)*. 2015;90(11):546-548.
4. Shaikh IS, Elsamna ST, Zarbin MA, Bhagat N. Assessing the risk of stroke development following retinal artery occlusion. *Journal of stroke and cerebrovascular diseases*. 2020;29(9):105002.
5. Brown SM. Stroke Risk and Risk Factors in Patients With Central Retinal Artery Occlusion. *American Journal of Ophthalmology*. 2019;200:252.
6. Chodnicki KD, Pulido JS, Hodge DO, Klaas JP, Chen JJ, editors. Stroke risk before and after central retinal artery occlusion in a US cohort. *Mayo Clinic Proceedings*; 2019: Elsevier.
7. Woo S, Lip G, Lip P. Associations of retinal artery occlusion and retinal vein occlusion to mortality, stroke, and myocardial infarction: a systematic review. *Eye*. 2016;30(8):1031-1038.
8. Bacigalupi M. Amaurosis fugax-A clinical review. *Internet Journal of Allied Health Sciences and Practice*. 2006;4(2):6.
9. Hayreh SS, Zimmerman MB. Amaurosis fugax in ocular vascular occlusive disorders: prevalence and pathogenesis. *Retina*. 2014;34(1):115-122.
10. Varma D, Cugati S, Lee A, Chen C. A review of central retinal artery occlusion: clinical presentation and Management. *Eye*. 2013;27(6):688-697.
11. Chen S-N, Hwang J-F, Chen Y-T. Macular thickness measurements in

- central retinal artery occlusion by optical coherence tomography. *Retina*. 2011;31(4):730-737.
12. Ahn SJ, Woo SJ, Park KH, Jung C, Hong J-H, Han M-K. Retinal and choroidal changes and visual outcome in central retinal artery occlusion: an optical coherence tomography study. *American Journal of Ophthalmology*. 2015;159(4):667-676.
 13. Falkenberry SM, Ip MS, Blodi BA, Gunther JB. Optical coherence tomography findings in central retinal artery occlusion. *Ophthalmic Surgery, Lasers and Imaging Retina*. 2006;37(6):502-505.
 14. Arnold M, Koerner U, Remonda L, Nedeltchev K, Mattle H, Schroth G, et al. Comparison of intra-arterial thrombolysis with conventional treatment in patients with acute central retinal artery occlusion. *Journal of Neurology, Neurosurgery & Psychiatry*. 2005;76(2):196-199.
 15. Feltgen N, Neubauer A, Jurklics B, Schmoor C, Schmidt D, Wanke J, et al. Multicenter study of the European Assessment Group for Lysis in the Eye (EAGLE) for the treatment of central retinal artery occlusion: design issues and implications. EAGLE Study report no. 1. *Graefes Archive for Clinical and Experimental Ophthalmology*. 2006;244(8):950-956.
 16. Park SJ, Choi N-K, Yang BR, Park KH, Lee J, Jung S-Y, et al. Risk and risk periods for stroke and acute myocardial infarction in patients with central retinal artery occlusion. *Ophthalmology*. 2015;122(11):2336-2343.
 17. Lavin P, Patrylo M, Hollar M, Espaillat KB, Kirshner H, Schrag M. Stroke risk and risk factors in patients with central retinal artery occlusion. *American Journal of Ophthalmology*. 2018;196:96-100.
 18. Lee KE, Tschoe C, Coffman SA, Kittel C, Brown PA, Vu Q, et al. Management of acute central retinal artery occlusion, a "retinal stroke": an institutional series and literature review. *Journal of Stroke and Cerebrovascular Diseases*. 2021;30(2):105531.

nursalim turnitin result 24.06.2022

ORIGINALITY REPORT

17%

SIMILARITY INDEX

12%

INTERNET SOURCES

13%

PUBLICATIONS

5%

STUDENT PAPERS

PRIMARY SOURCES

1	Submitted to Universitas Indonesia Student Paper	3%
2	ejournal.upnvj.ac.id Internet Source	2%
3	Brian Mac Grory, Matthew Schrag, Sven Poli, Chantal J. Boisvert et al. "Structural and Functional Imaging of the Retina in Central Retinal Artery Occlusion – Current Approaches and Future Directions", Journal of Stroke and Cerebrovascular Diseases, 2021 Publication	2%
4	www.nature.com Internet Source	2%
5	"From the 16th International Neuro-ophthalmology Society (INOS) Congress 2006", Neuro-Ophthalmology, 2009 Publication	1%
6	synapse.koreamed.org Internet Source	1%

7	Mehrdad Malihi, Roger E. Turbin, Larry P. Frohman. "Saturday Night Retinopathy with Ophthalmoplegia: A Case Series", Neuro-Ophthalmology, 2015 Publication	1 %
8	Ocular Vascular Occlusive Disorders, 2015. Publication	1 %
9	iqjmc.uobaghdad.edu.iq Internet Source	1 %
10	Farzan Kianersi, Heshmatollah Ghanbari, Afsaneh Naderi Beni, Zahra Naderi Beni, Hamid fesharaki, Mostafa Ahmadi. "MACULAR BRANCH RETINAL ARTERY OCCLUSION AS THE FIRST MANIFESTATION OF OCULAR TOXOPLASMOSIS", Retinal Cases & Brief Reports, 2013 Publication	1 %
11	www.frontiersin.org Internet Source	1 %
12	"Neuro-Ophthalmology", Springer Science and Business Media LLC, 2019 Publication	1 %
13	Amir Hadanny, Amit Maliar, Gregory Fishlev, Yair Bechor, Jacob Bergan, Mony Friedman, Isaac Avni, Shai Efrati. "Reversibility of retinal ischemia due to central retinal artery	1 %

occlusion by hyperbaric oxygen", Clinical Ophthalmology, 2016

Publication

14

Gyojun Hwang, Se Joon Woo, Cheolkyu Jung, Kyu Hyung Park, Jeong-Min Hwang, O-Ki Kwon. "Intra-arterial Thrombolysis for Central Retinal Artery Occlusion: Two Cases Report", Journal of Korean Medical Science, 2010

Publication

15

Kim, Yong Woo, Se Joon Woo, Jeeyun Ahn, Kyu Hyung Park, and O-Ki Kwon. "Ophthalmic Artery Aneurysm: Potential Culprit of Central Retinal Artery Occlusion", Korean Journal of Ophthalmology, 2013.

Publication

16

Ivonne Elisabeth Rotty, Erwin Kristanto, Sekplin Sekeon, Henny Ruth Liwe, Neni Ekawardani. "COVID-19: Comparison of immunogenicity response between natural and post-vaccination infections", F1000Research, 2022

Publication

17

"From the 8th European Neuro-Ophthalmology Society (EUNOS) Meeting", Neuro-Ophthalmology, 2007.

Publication

18

D D Varma, S Cugati, A W Lee, C S Chen. "A review of central retinal artery occlusion:

1 %

1 %

<1 %

<1 %

<1 %

clinical presentation and management", Eye, 2013

Publication

Exclude quotes On

Exclude matches Off

Exclude bibliography On