
GAS-CONTAINING KIDNEY STONES: A CASE REPORT**Putu Herry Juniada^{1*}, Ni Nyoman Srie Laksminingsih¹, I Made Dwijaputra Ayusta¹**¹Fakultas Kedokteran, Universitas Udayana-RSUP Sanglah Denpasar, Bali, Indonesia*Correspondence email: herryjuniada@gmail.com

ABSTRACT

Gas-containing kidney stones are rare cases. The available literature about gas in the kidneys, usually only discusses and distinguishes between two things, namely emphysematous pyelonephritis and emphysematous pyelitis, after getting rid of recent upper urinary tract instrumentation and the presence of fistula with the gastrointestinal tract. To date, there have been only 11 cases of gas-containing kidney stones. We report the 12th case of gas-containing kidney stones (the first from the field of radiology), which is a 69-year-old female with bilateral flank pain, no fever, and no history of other diseases. Physical examination revealed bilateral costovertebral angle tenderness. The plain abdominal radiograph showed a staghorn stone in the right kidney. The non-enhanced CT abdomen showed gas-containing staghorn stones in the right kidney accompanied by hydronephrosis. The patient underwent percutaneous nephrolithotomy. Kidney stone analysis showed oxalate, phosphate, ammonium, calcium, and uric acid components. The etiology and relationship of gas-containing kidney stones with other gas entities in the kidney is still unclear, making it difficult to determine their clinical significance. Radiological examination, especially CT scan, plays a very important role in determining the entity of gas in the kidney.

Keywords: Kidney stone; Gas-containing; Emphysematous pyelonephritis.

INTRODUCTION

Gas-containing kidney stones are very rare cases. The available literature about gas in the kidneys, usually only discusses and distinguishes between 2 things, namely emphysematous pyelonephritis and emphysematous pyelitis, after excluding the history of procedures on the upper urinary tract and the presence of fistulas with the gastrointestinal tract.^{1,2} Emphysematous pyelonephritis is a condition in which gas is present in the renal parenchyma, spreading to the pelvicalyceal system and/or to the tissues surrounding the kidneys.^{1,2} While emphysematous pyelitis is a condition in which gas is confined to the pelvicalyceal system.^{1,2} Both of these conditions and other conditions of the spectrum of gas in the kidney are necessary to distinguish because emphysematous pyelonephritis is a life-threatening condition. To distinguish among them, radiological examination, especially CT scan, is needed. According to our knowledge,

there is no literature that discusses gas-containing kidney stones. Existing literature on gas-containing kidney stones is still in the form of case reports. To date, only 11 cases of gas-containing kidney stones have been reported from the field of urology.⁵⁻¹¹ The pathophysiology of the gas-containing kidney stones and whether it is related to emphysematous pyelonephritis, which is known to be very life-threatening, is not known certainly.

CASE REPORT

We report the 12th case of gas-containing kidney stones (but the first from the field of radiology), a 69-years-old woman with complaints of low back pain, no fever, no history of other diseases. On physical examination, bilateral costovertebral angle tenderness was found, vital signs were within normal limits. A plain radiograph of the abdomen showed staghorn stones of the right kidney and multiple nephrolithiasis of the left

kidney, accompanied by lumbar spondylosis (Figure 1). Computed tomography of kidneys, ureters, and bladder (CT KUB) without contrast showed staghorn stones with gas components in it, accompanied by hydronephrosis of the right kidney (Figure 2), as well as stones at the left ureteropelvic junction and multiple stones in the middle and lower poles of the left kidney with a widening of the pelviocalyceal system and contracted left kidney, no perinephric stranding was seen. Abdominal aorta and bilateral iliac artery atherosclerosis, multiple cholelithiasis, and lumbar spondylosis were also seen. Laboratory examinations showed an increase in urine sediment leukocytes, serum creatinine, and uric acid, a decrease in hemoglobin levels (low serum iron and TIBC, high ferritin), while other laboratory tests were within normal limits.

The patient then underwent percutaneous nephrolithotomy with the placement of a right DJ stent. On the postoperative plain radiograph, the stone was still visible in the right and left kidneys, but the stone component in the right renal pelvis was removed, and a DJ stent was attached (Figure 3). From the analysis of kidney stones obtained components of oxalate, phosphate, ammonium, calcium, and uric acid. The patient was also given medical therapy in the form of antibiotics cefazolin 2 x 1gr (i.v) and allopurinol 1 x 100 mg (p.o), folic acid 2 x 2 mg (p.o).

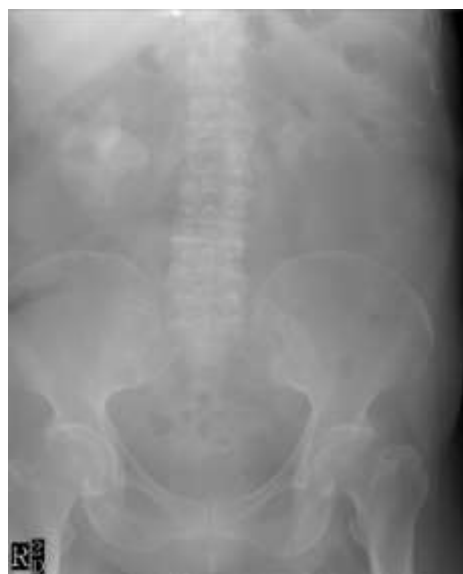

Figure 1. A plain abdominal radiograph showed staghorn stones in the right kidney and multiple nephrolithiasis in the left kidney, accompanied by lumbar spondylosis

DISCUSSION

Gas in the genitourinary system may be caused by an infection that produces gas, infarction, the presence of fistula with hollow organ, or by the entry of air from outside the body (atmosphere) through instrumentation of the genitourinary system, surgery, or puncture trauma (Table 1).¹

Renal emphysema is a condition of spontaneous gas formation in the parenchyma or tissue around the kidneys, so the spectrum includes:¹

1. Formation of gas in the kidney parenchyma (emphysematous pyelonephritis)
2. Formation of gas confined to the pelviocalyceal system (emphysematous pyelitis)
3. Formation of gas in the tissues around the kidneys (perinephric emphysema or abscess)

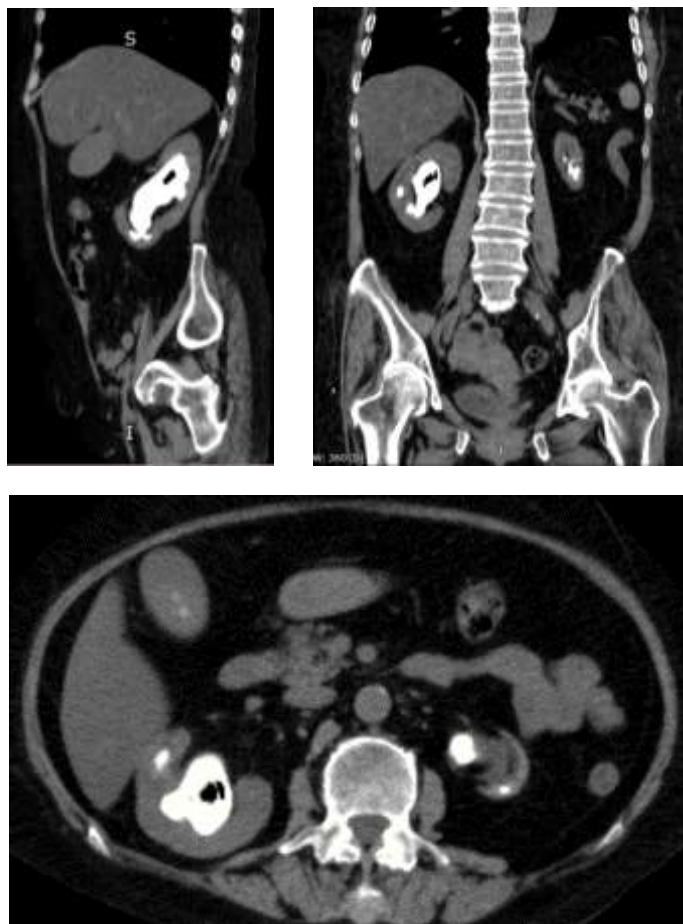

Figure 2. CT KUB without contrast showed a staghorn stone with a gas component in it accompanied by hydronephrosis of the right kidney. There was no visible gas in the parenchyma or the remaining collecting system. There were also stones at the left ureteropelvic junction and multiple stones in the middle and lower poles of the left kidney with hydronephrosis and contracted left kidney, as well as multiple cholelithiasis.

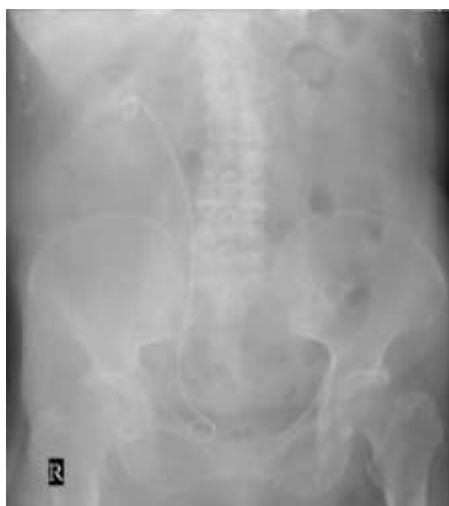

Figure 3. Postoperative plain photo, there are still stones in the right and left kidneys, but the stone component in the right renal pelvis has been removed, and a DJ stent is installed.

Emphysematous pyelonephritis is a life-threatening condition, defined as an acute suppurative necrotic infection with gas formation in the renal parenchyma. In emphysematous pyelonephritis gas can be found not limited to the renal parenchyma. Gas-forming infections can cause gas to form in the pelvicalyceal system, renal parenchyma, and/or perirenal tissues. Therefore, it is very important to differentiate emphysematous pyelonephritis, especially from emphysematous pyelitis, which is a gas-forming infection that is limited to the pelvicalyceal system.²

Table 1. Causes of Gas in the Genitourinary System¹

Infection (gas-forming organisms)	
Kidney	Emphysematous pyelonephritis
	Emphysematous pyelitis
	Abscess
	Perinephric emphysema
Bladder	Emphysematous cystitis
Uterus and ovaries	Endometritis
	Infarcted or infected tumor
Scrotum, testicle, and prostate	Abscess
	Fournier gangrene
Iatrogenic	
	Surgical procedure
	Radiologic procedure
	Infarction of renal carcinoma (therapeutic or spontaneous)
Penetrating trauma	
Reno-gastrointestinal tract fistula	
	Inflammatory (diverticulitis, Crohn disease)
	Neoplastic

Emphysematous pyelonephritis is characterized by fever, low back pain, and systemic disorders. Predisposing factors for emphysematous pyelonephritis include diabetes mellitus, urinary tract obstruction, immunocompromise, alcohol and substance abuse, and neurogenic bladder. High blood sugar levels in tissues can cause impaired blood flow and immune response, thereby increasing the fermentation of glucose and

lactate by gram-negative bacteria to produce carbon dioxide, which is the hallmark of this condition. Urinary tract obstruction can increase the risk of urinary tract infections due to urinary stasis. The higher incidence of emphysematous pyelonephritis in women may be related to the higher incidence of urinary tract infections in women. The most common causative organism is *E. coli*. Besides *E. coli*, *Klebsiella pneumoniae*, *Proteus mirabilis*, *Enterococcus*, *Pseudomonas*, *Citrobacter*, *Streptococcus*, *Staphylococcus*, anaerobic organisms (*Clostridium*), and fungi (*Candida*), have also been isolated from urine cultures of patients with emphysematous pyelonephritis.²

Imaging plays an important role in distinguishing various entities in the spectrum of gas in the kidney. The gold standard is a CT scan of the abdomen/pelvis with contrast to identify the presence of gas in the parenchyma, pelvicalyceal system, and/or in the tissues surrounding the kidneys (Figure 4, 5), or further to identify the presence of hydronephrosis or ureteral obstruction. However, in conditions of increased serum creatinine levels which are often found in patients with emphysematous pyelonephritis, CT KUB (without contrast) can still identify gas and/or stones in the kidney. There are several classification systems for emphysematous pyelonephritis, and the two most recent are according to Wan et al. and Huang et al. (Table 2).²

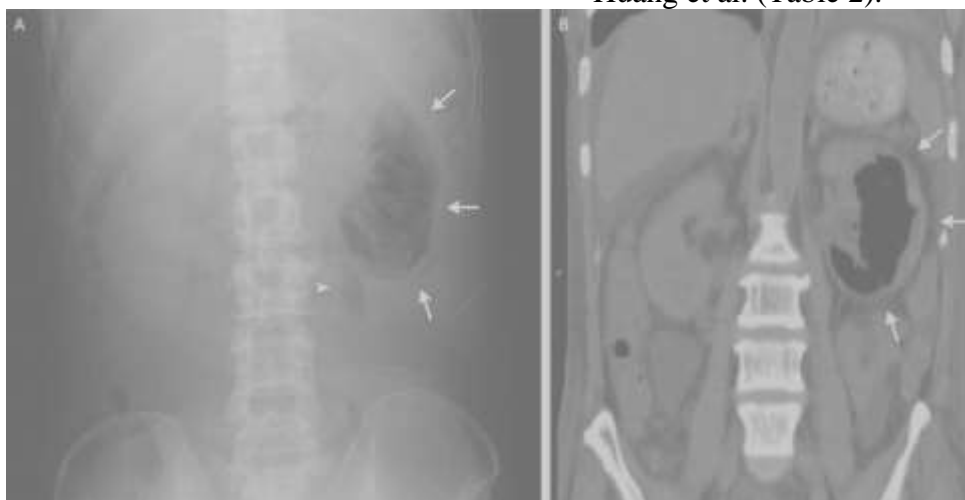


Figure 4. Plain radiographs and abdominal CT showing gas in the parenchyma and perinephric cavity of the left kidney³

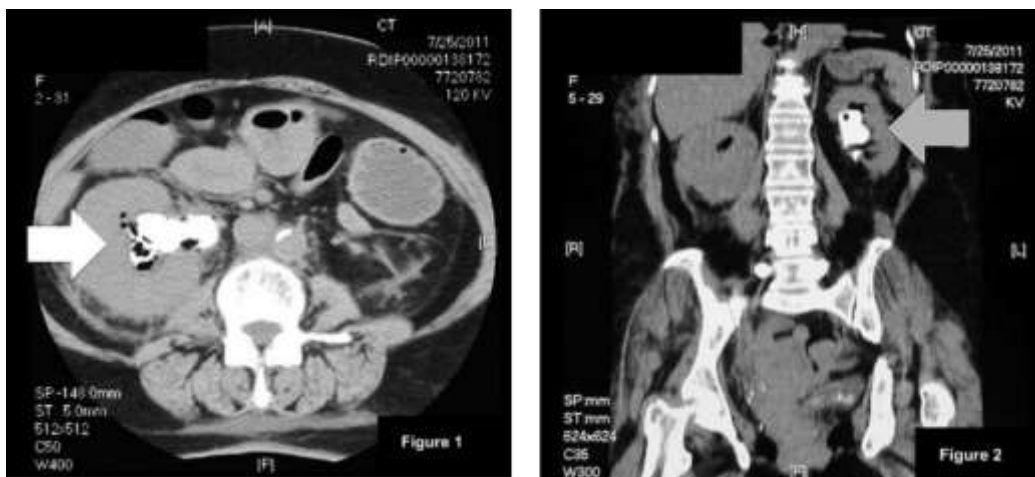


Figure 5. CT scan shows staghorn stones with gas in the pelvicalyceal system of the right and left kidneys⁴

Table 2. Classification of Emphysematous Pyelonephritis Using CT scan with Contrast²

	Grade I	Grade II		
Wan et al., 1998 [15]	Renal necrosis with presence of gas but no fluid	Parenchymal gas associated with fluid		
	Grade 1	Grade 2	Grade 3	Grade 4
Huang et al., 2000 [2]	Gas in the collecting system only	Parenchymal gas only	A) Extension of gas into perinephric space B) Extension of gas into pararenal space	Bilateral EPN or EPN in solitary kidney
	Increasing mortality [2]			

Inadequate management of sepsis in patients with emphysematous pyelonephritis can be fatal. Therefore, the initial management of patients with emphysematous pyelonephritis includes oxygen therapy, correction of fluid and acid-base abnormalities. Because diabetes mellitus is a major predisposing factor, controlling blood sugar levels is important, and is usually achieved with insulin therapy. Immunosuppression (as in HIV patients and organ transplant recipients) is also a risk factor, so lowering the steroid dose should be considered. The appropriate antibiotic therapy of choice is that which includes gram-negative bacteria, especially *E. coli* (aminoglycosides, cephalosporins, and quinolones). If the diagnosis is confirmed, then surgical intervention is performed. As the gold standard, percutaneous intervention is performed to drain abscesses and gas. In

patients with hydronephrosis, decompression is performed with a nephrostomy or DJ stent. In patients with two risk factors whose CT scan shows >50% renal pelvic damage or with emphysematous pyelonephritis grade 3 or 4, nephrectomy should be considered (Figure 6).²

In our case, the CT scan confirmed that the gas was only in the kidney stone. In some previous cases, gas was found in and around the kidney stones, so there is an assumption that gas-containing kidney stones are a variant or early stage of emphysematous pyelonephritis. In some cases previously, the patient reported with sepsis, but in other cases, including our case, the patient only complained of flank pain with costovertebral angle tenderness. Cases of gas-containing kidney stones are usually associated with recurrent urinary tract infections. In our case, there was also a urinary tract infection, thus

supporting the hypothesis that certain gas-producing bacterial infections cause gas-containing kidney stones. However, unfortunately in our case, urine culture was not examined to determine the type of germ. Hydronephrosis due to urinary obstruction by kidney stones that occurred in this case and all previous cases, increased the risk of infection. Certain comorbid diseases, such as diabetes mellitus, hyperuricemia, hyperparathyroidism, and sarcoidosis, can increase the risk of

developing kidney stones. In our case, only hyperuricemia was found, which was supported by the finding of a uric acid component in kidney stone analysis. Another finding in our case, such as increased serum creatinine, is a sign of acute chronic kidney disease ec. post-renal due to obstruction of kidney stones. This will lead to anemia in chronic disease, which is confirmed by a decrease in serum iron and TIBC with an increase in ferritin.⁵⁻¹¹

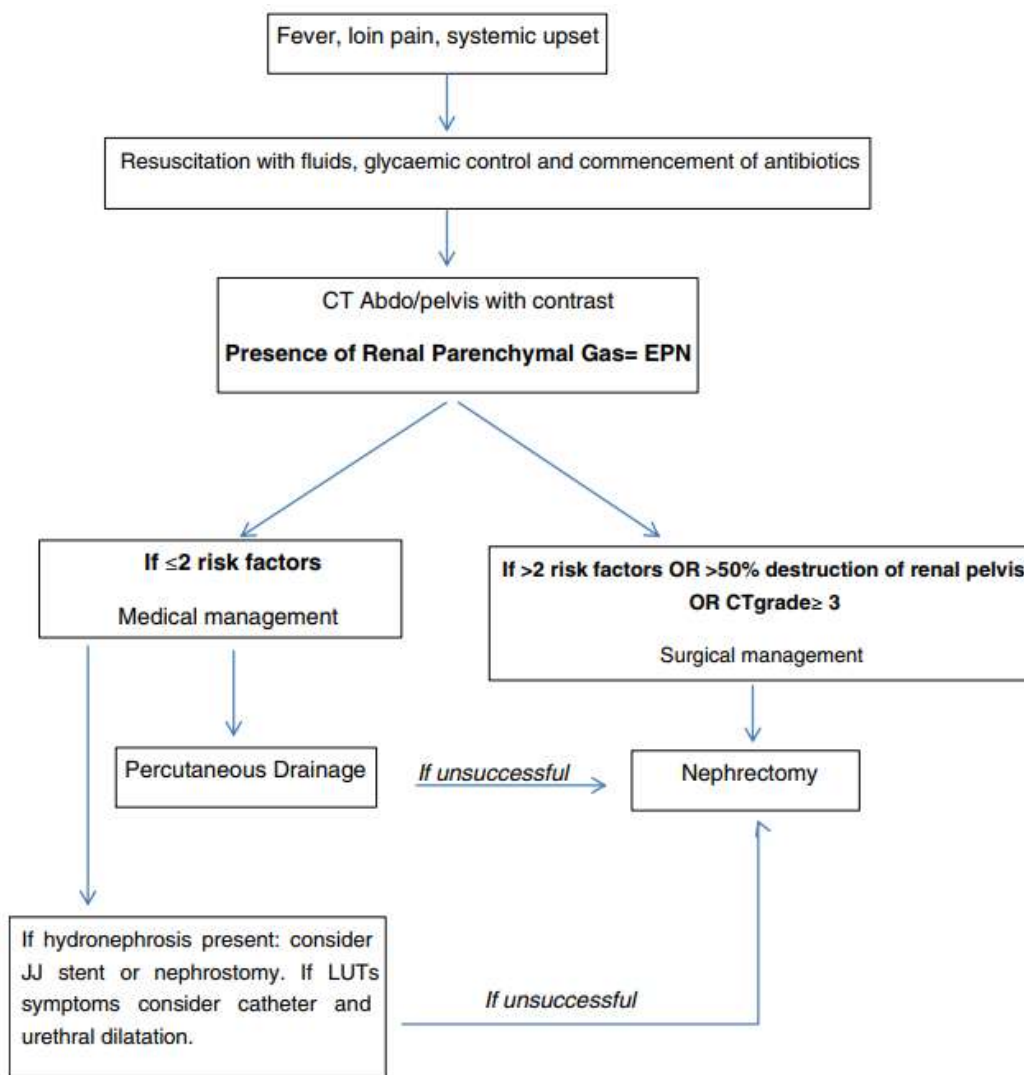


Figure 6. Emphysematous Pyelonephritis Treatment Algorithm²

According to the algorithm, this patient underwent decompression with percutaneous nephrolithotomy with the installation of a DJ stent in the right kidney. They were followed by administering intravenous antibiotics cefazolin, which belongs to the class of first-generation cephalosporin antibiotics that

cover gram-negative bacteria, including E. coli, to eradicate infection and prevent disease progression.² The patient was also given allopurinol therapy as a therapy for hyperuricemia and folic acid as supportive therapy for chronic kidney disease. This patient did not receive initial treatment of

systemic resuscitation (such as oxygen therapy, correction of fluid, and acid-base abnormalities) because this patient was not/not yet in a state of sepsis or had emphysema pyelonephritis.

CONCLUSION

Gas-containing kidney stones are a very rare condition. The etiology and association with other gas entities in the kidney remain unclear, making it difficult to determine their clinical significance. The suspicion that this gas-containing kidney stone is a variant or early stage of emphysematous pyelonephritis makes it an important entity to be recognized, identified, and treated appropriately, considering that emphysematous pyelonephritis is a life-threatening condition. Radiological examination, especially CT scan, plays a very important role in differentiating gas entities in the kidney.

REFERENCES

1. Joseph RC, Amendola MA, Artze ME, Casillas J, Jafri ZH, Dickson PR, Morillo G. Genitourinary Tract Gas: Imaging Evaluation. *RadioGraphics* 1996; 16:295-308. <https://doi.org/10.1148/radiographics.16.2.8966288>.
2. Mahesan T, Reddy UD, Chetwood A, Emara AM. Emphysematous Pyelonephritis: a Review of a Rare Condition. *Curr Bladder Dysfunct Rep* 2015; 10:207–211. : <https://doi.org/10.1007/s11884-015-0303-x>.
3. Hirose Y, Kaida H. Emphysematous Pyelonephritis. *N Engl J Med* 2016; 375:1671. <https://doi.org/10.1056/NEJMicm1501812>.
4. Tan GH, Ho CCK, Bahadzor B, Praveen S, Goh EH, Syahril AS, Zulkifli MZ. Case Report, Bilateral emphysematous pyelitis: a rare encounter in urology. *Clin Ter* 2013; 164 (4):197-199. <https://doi.org/10.7417/CT.2013.1580>.
5. Simpson AD, Rytina ER, Ball RY, Gaches CG. Stones, gas and gaiters: gas-filled matrix calculi of the renal pelvis. *Br J Urol.* 1998; 81:770–772. <https://doi.org/10.1046/j.1464-410x.1998.00594.x>.
6. Nilsen F, Karlsen S, Gjertsen O. Gas-containing renal stones treated with percutaneous nephrostolithotomy: case report. *J Endourol.* 2001; 15:915–917. <https://doi.org/10.1089/089277901753284134>.
7. Paterson R, Welsch J, Koerner T, Lingeman J. Urinary calculus containing gas. *Urol.* 2002; 60:164iii–164v. [https://doi.org/10.1016/s0090-4295\(02\)01666-7](https://doi.org/10.1016/s0090-4295(02)01666-7).
8. Rapoport M, Sadah A. Gas-containing renal stones. *J Urol.* 2006; 68:890.e13–890.e15. <https://doi.org/10/1016/j.Urology.2006.05.017>.
9. Manny TB, Mufarrij PW, Lange JN, Mirzazadeh M, Hemal AK, Assimos DG. Gascontaining renal stones: findings from five consecutive patients. *Urology.*2012;80(6):1203–1208. <https://doi.org/10.1016/j.urology.2012.08.035>.
10. Wazzan MA, Abduljabbar AH. Gas containing renal stone – case report. *Urology Case Reports* 25 (2019) 100887:1-5. <https://doi.org/10.1016/j.eucr.2019.100887>.
11. Peter J, Bhat S, Paul F. Gas-containing renal stones. *Indian J Urol* 2020;36:67-8. https://doi.org/10.4103/iju.IJU_271_19.