
CHROMOBLASTOMYCOSIS TREATMENT WITH COMBINATION THERAPY OF ITRACONAZOLE (PULSE DOSE) AND CRYOTHERAPY

Nugrohoaji Dharmawan¹, Ahmad Fiqri^{1*}

¹Departemen Dermatovenereologi, Dr. Moewardi General Hospital, Fakultas Kedokteran, Universitas Sebelas Maret, Surakarta, 57126, Indonesia

*Correspondence email: Ahmad Fiqri (ach.vkr3.af@gmail.com)

ABSTRACT

Chromoblastomycosis is a chronic mycosis infection of the skin and subcutaneous tissue. The lesion begins with a history of trauma characterized by slowly gradual growing nodule lesions, especially in the lower extremities. Management of chromoblastomycosis may be physical and non-physical and combination to achieve the best result. A 70-year-old male farmer came with a rough lump on his left leg in the past six years ago. Lesions were multiple-verrucous, varying sizes nodules on the left limb. Skin scrapings examination showed copper penny appearance or Medlar bodies. Histopathological examination showed granulomatous inflammation and Medlar bodies. In fungi culture, we obtained *Fonsecaea pedrosoi*. Patients were treated with a combination of Itraconazole 400 mg/day for a week for three months (pulse dose) and serial cryosurgery once per week. The combination therapy gave clinical improvement and good results. The diagnosis of chromoblastomycosis is based on history, physical examination, histopathology, and culture. Predisposing factors are working in the fields in this case and being exposed to trauma such as soil and plants. Giving combination therapy with itraconazole and cryosurgery makes good results for this patient.

Keywords: Chromoblastomycosis; Cryosurgery; *Fonsecaea pedrosoi*; Itraconazole.

INTRODUCTION

Chromoblastomycosis is a chronic profound fungal infection on skin and subcutaneous tissue, characterized by papular lesions, plaque, and verrucous nodules that are slowly growing. Medlar body can be found on skin scraping. Histopathological examination showed Medlar body from tissue, particularly affecting leg and leg. Chromoblastomycosis is rarely found.¹

The aetiology of chromoblastomycosis is dark-pigmented fungi / dermaticeae fungi / black fungi, including *Fonsecaea pedrosoi*, *Fonsecaea compactum*, *Wangiella dermatitis*, and *Cladophialophora carrionii*.¹ Chromoblastomycosis can result from environments such as wood, plant, and soil. Primary inoculation can occur through network trauma, with predilection on lower extremities generally.^{2,3}

Chromoblastomycosis is found in tropical and subtropical states like America, Africa, Australia, and India. Japan has the highest chromoblastomycosis incidence among 1,416,000 Asian populations.³ Two chromoblastomycosis cases were reported by Sansan et al. in the Dermatology Clinic of Dr. Moewardi Hospital Surakarta between 2010-2011.⁴ The prevalence is higher in male adults than in women and children, and it is often attributed to patients' occupation.⁵ More than half of the cases occur in adults aged 30-60 years. Patient's occupation is generally related to soil, tending to develop trauma, such as farmer, gardener, wood seeker in the jungle, labour of animal husbandry, etc.^{1,2}

Chromoblastomycosis is a variable clinical presentation. Generally, the primary lesion is warty papule accompanied with slowly developing squamous tissue and then progressively changing into polymorph

constituting nodule, tumour, verrucous, plaque, or cicatrix.^{2,5}

Work up is conducted with KOH 10% of infected skin tissue, indicating oval or spherical single and colony spore fungi fragment, with thick wall and blackish-brown colour.⁶ Macroscopic examination on fungus culture finds bright brown filament colony and brown sclerotic/medlar body, while microscopic observation finds long partitioned hypha with ramification conidia. Histopathological examination reveals pseudoepitheliomatous epidermal hyperplasia and broad dermal infiltrates consisting of epithelioid histiocyte cells rather than neutrophil and lymphocyte cells. Thick-walled spore seems to be round or oval-shaped blackish-brown that can be single or in the colony, called copper penny appearance or Medlar body.²⁻⁷

Patients with chromoblastomycosis are still a true therapeutic challenge for clinicians due to the recalcitrant nature of the disease, especially in the severe clinical forms.³ Oral itraconazole (pulse dose) 200-400 mg/day shown clinical and mycological cure after 10.9 months on 30 Brazilian people. A reported study of cryosurgery with itraconazole with 22 cases achieved a mycological and clinical cure rate of 40.9%, so they are currently being the best combination.³ This paper reports a chromoblastomycosis case in a 70-year old man who had the disease for six years. He also got clinical improvement with combined itraconazole and cryosurgery (frozen section) therapy.

CASE REPORT

A 70-year male farmer who lived in Semarang, Central Java, came to the Dermatovenereology Department of Dr. Moewardi Hospital, Surakarta, with a chief complaint of a lump on the left leg. The patient said that it had begun 6 (six) years ago. One month ago, he had sought some clinicians, but the complaint did not improve.

The patient had no history of chronic cough, food allergy, asthma, diabetes

mellitus, or hypertension. The family history was also denied.

From the physical examination, we found well general condition, compos mentis awareness, and vital signs are normal. In dermatological examination on the left ankle region, we found multiple hyperpigmented nodules with the verrucous surface (Figure 1). We could propose the differential diagnoses of the case were chromoblastomycosis and squamous cell carcinoma taken from the history and physical examination.

The routine blood laboratory was within normal limits. X-ray imaging showed a normal result. KOH 10% examination on the tissue indicated oval, spherical single and colony spores, discovered thick wall and blackish-brown colour appearance leading to chromoblastomycosis (Figure 2). Biopsy was conducted on this patient by taking skin tissue on the left ankle region, in 1.5 cm size, with brown colour. Then, histopathological examination was performed using hematoxylin-eosin (HE) staining, obtaining granulomatous inflammation, and pseudoepitheliomatous hyperplasia was found in 10x magnification. The 40x magnification revealed inflammatory cell infiltration and Medlar body / Copper penny representation. The 100x magnification indicates Medlar body/copper penny and no malignancy sign (Figure 3. A-C). Periodic acid shift (PAS) staining with 40x and 100x magnifications indicated pale-colour spores (positive PAS) with the conclusion supporting chromoblastomycosis (Figure 3. D-E).

The examination of fungi culture using Sabouraud Dextrose Agar (SDA) macroscopically reveals a brown filament colony. The culture slide microscopically indicated long branching filamentous hypha with conidia, consistent with *Fonsecaea pedrosoi* (Figure 4). Considering anamnesis, physical examination, and supporting examination, this patient was diagnosed with chromoblastomycosis. The patient underwent oral itraconazole 400 mg/day therapy within a week for three months (pulse dose) and 1-cycle / week cryotherapy with a minute duration (Figure 5,6,7). The patient's lesion

seemed to improve following cryotherapy and itraconazole therapy (pulse dose) processes.

KOH 10% examination showed no spore (Figure 8).

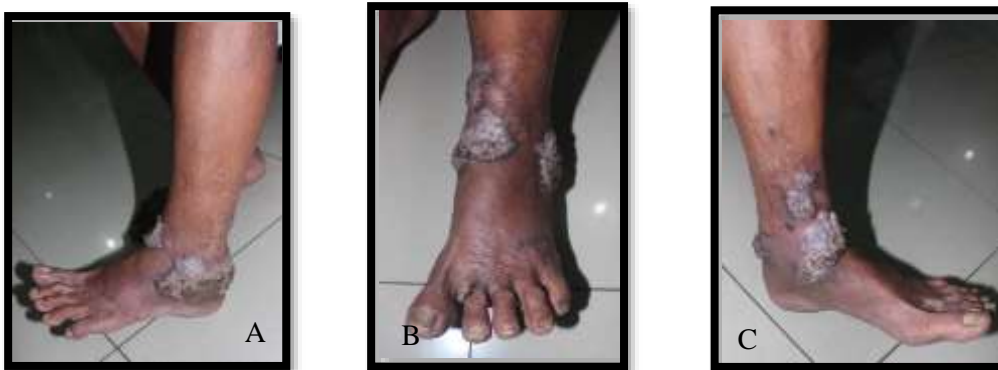

Figure 1. (A-C) Local state of left ankle region showed multiple hyperpigmented nodules with verrucous a surface.

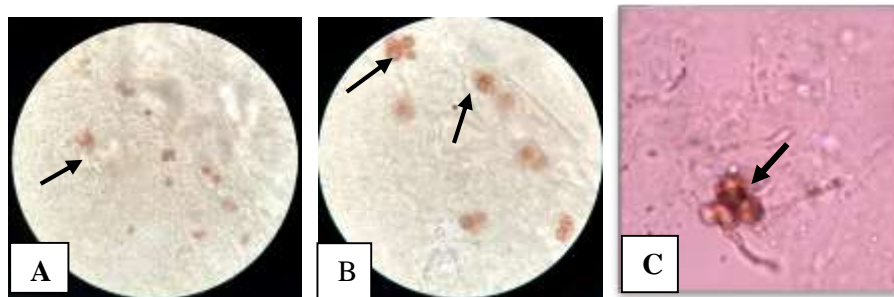


Figure 2. Microscopic result of 10% KOH taken from infected skin scraping on verrucous nodule lesion (A, B, C) indicating Medlar body/copper penny.

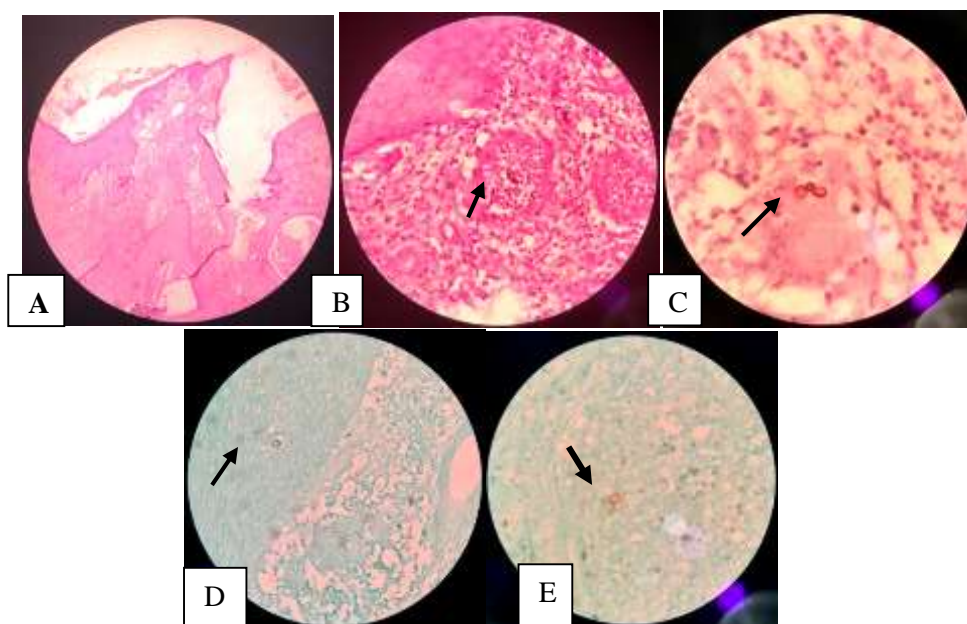


Figure 3. (A). 10x magnification with HE;(B). 40x magnification with HE; (C). 100x magnification with HE; (D). 40x magnification with PAS; (E). 100x magnification with PAS.

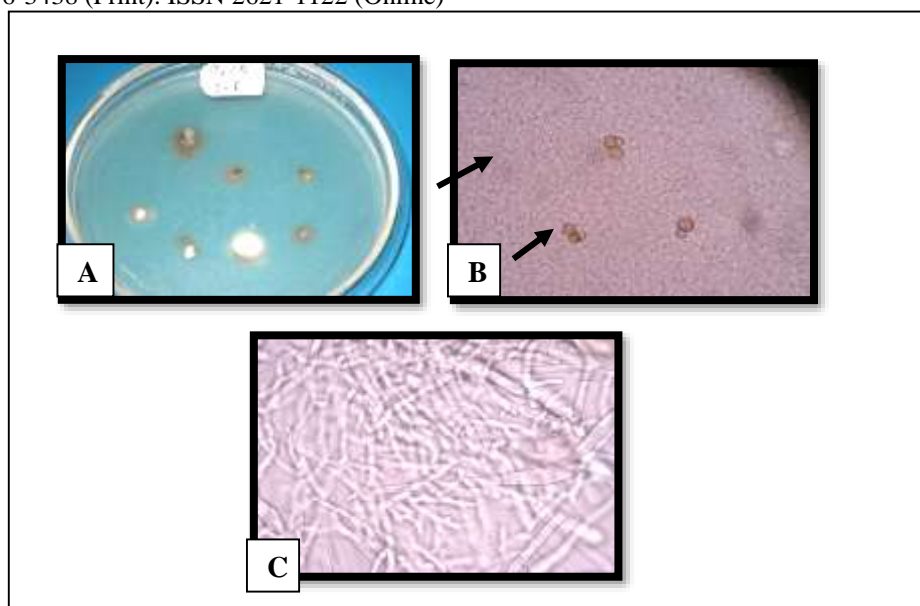


Figure 4. Culture result on Sabouraud Dextrose agar (SDA) media taken from infected skin tissue, (A) Macroscopically indicates bright brown filament. (B) Microscopically shows brown Medlar body, (C) On culture slide, macroscopically indicates long branching filamentous hypha with conidia.

DISCUSSION

Chromoblastomycosis/chromomycosis / verrucous dermatitis is a Geraniaceae-induced fungal disease. Some fungus species belonging to *dermaticeae* are *Phiaophora verrucosa*, *Fonsecae pedrosoi*, *Fonsecae compactum*, *Wangiella dermatitidis*, *Cladosporium carrionii* and *Rhinochrysiella aquaspresa*.^{1,8} This fungal group is dark brown to blackish-brown coloured and creates a filamentous colony. The fungi live on soil, wood, and decomposed plants. This infection occurs due to direct inoculation from fungi into the skin.^{1,6,7}

Chromoblastomycosis is found sporadically in South America and Central America, rarely in North America. It occurs in Caribbean, African, Australian, and Japanese areas. This infection often occurs, particularly in rural male workers. Most cases were reported in tropical and humid subtropical climate areas such as America, Asia, and Africa. The highest prevalence rate is reported in Mexico, Cuba, Venezuela, Colombia, and Brazil.^{8,9} Japan has the highest incidence rate among the Asian populations with a ratio of 1: 416,000 people.³ In tropic and subtropic countries, it occurs more commonly in males aged 30-60 years working in the farming sector (about 70% of the cases) because they

are risky of being injured by the part of the plant constituting the factor causing it. The incidence ratio of males to females is 1: 0.8 in Japan.^{10,11} It mostly affects the upper part of the body, buttock, limb, and particularly the leg, which most frequently has contact with the material containing fungi such as soil, plant, or decomposed wood.¹²

The lesion is gradually expanding the papule and creates hyperkeratosis plaque.^{2,5,13} Some of these plaque lesions are flat and spread gradually with scars around the lesion center. The initial lesion can be an ulcer. Then, some months or years later, large hyperkeratosis is created with about 2-3 cm thickness. A secondary ulcer may occur; this lesion usually gives pain unless secondary bacterial infection occurs. It can result in itchiness and pain. Hematogenous spread may rarely occur, and brain abscess has never been found.^{2,3,13,14} Secondary infection will finally result in lymphatic stasis that changes into elephantiasis. Some lesions can be psoriasiform lesions.¹⁵ Squamous cell carcinoma may occur in chronic lesions.¹⁶ The most frequent form is verrucous lesion spreading gradually and locally.¹⁷ Technically, chromoblastomycosis diagnosis does not result in big trouble, but the meantime interval between disease outset and

diagnosis is chronic. Standardized diagnosis builds on the finding of Medlar body from the skin scraping, and microscopic culture or histopathology.^{2,3,17-20}

A similar complaint is found in this case, like a lump and itchiness on the patient's left leg, having persisted for years. The lesion complained of is getting bigger and wider over time. The result of physical examination also confirms chromoblastomycosis presentation in which there are multiple hyperpigmented nodules with the verrucous surface. In addition to history taking and physical examination, chromoblastomycosis diagnosis can be established with a skin scraping examination using KOH 10% with oval or spherical spores, thick wall, and blackish-brown colour. The result of fungus culture using SDA media macroscopically shows bright brown filamentous colony and microscopically shows brownish Medlar body. The culture slide examination results show that long branching filamentous hypha with conidia is consistent with *Fonsecaea pedrosoi*. Similarly, histopathological examination with HE and PAS staining shows epidermal thickening (pseudo-epitheliomatous hyperplasia), granulomatous inflammation, and Medlar body.

Comparative diagnosis in this patient is squamous cell carcinoma (SCC).²¹ SCC is a malignant neoplasm resulting from epidermal suprabasal keratinocytes abnormality.²² Generally, SCC often occurs in 40-50 years of age with the areas exposed more to sunlight like face, ears, lower lip, back, hand, and lower limb. The presentation of SCC includes easily bleeding reddish ulcerated nodule or verrucous plaque/papule indicating cornification and or hyperkeratosis signs. Histopathological examination showed SCC consists of irregular mass composing proliferating epidemic cells invading dermis. The well-differentiated SCC indicates fast keratinization on the squamous cellular layer. Tumour cells are focally and concentrically, followed by keratin mass, creating typical horn pearls on SCC. Comparative diagnosis of squamous cell carcinoma can be overridden from histopathological examination, finding

no image of horn pearls and or malignancy cells.^{22,23}

Chromoblastomycosis treatment can be both physical and non-physical.¹¹ Physical therapy can include standardized or excision surgery with margin and appropriate electrodesiccation curettage for the small and clearly-bordered lesion.²⁴ Another physical therapy is local thermal therapy. It is based on fungi like *F. pedrosoi*, vulnerable to high temperatures. Using a hot chemical pouch for one month with a bandage on the lesion for 24 hours per day results in the lesion improvement, while total resolution occurs on the second month. Cold therapy or cryotherapy is the best physical therapy, particularly when it is combined with systemic/chemotherapy anti-fungal agent because the disease spreading has been reported during the treatment with cryotherapy only.^{23,24} Cryotherapy uses liquid nitrogen, the coldest cryogenic agent with the largest freezing ability, to stimulate inflammatory reaction and necrosis on the affected tissue. Cryotherapy is recommended, particularly to the larger one (15 cm²). It should be conducted in different part and time intervals. According to the lesion width, the freezing time for cryotherapy using liquid nitrogen ranges between 30 seconds and 4 minutes.²³ In this case, cryotherapy is conducted with a freezing time of 1 (one) minute in one therapeutic cycle per week.

In addition to enhancing physical therapy, chromoblastomycosis can also be treated using chemotherapy, including 5-Fluorocytosine (5FC), with the recommended dose ranging between 100 and 150 mg/kg/day divided into four doses for 6-12 months, and topical 5FC can also be used. Itraconazole can also be used with the recommended dose ranging between 200-400 mg/day dependent on lesion severity and therapy until improvement is achieved (3 months to 1 year).^{11,23} The use of itraconazole in pulse dose regime (400 mg/day in a week for a month) has been succeeded in some cases.¹¹ Other drugs like Terbinafine with a dose of 250-500 mg/day and flucytosine of 150-200 mg/kg BW/day divided into four doses can

also be used.²⁴ Other evidence explains that the use of Terbinafine 250 mg is more effective. Tiabendazole is another alternative, but it is not tolerable to patients due to its side effect on the gastrointestinal tract.²³

Therapy combination should be considered for patients with chromoblastomycosis. Surgery method can heal but on another side also make spreading the disease.¹¹ Therefore, it is essential to apply additional chemotherapy, particularly itraconazole or Terbinafine. The combination of hot therapy and itraconazole can be a good choice, but cryotherapy along with itraconazole can be better, particularly on the wider lesion case. Itraconazole is applied until the maximum lesion reduction is achieved, occurring after 8-12 months of treatment, and then surgery can be done in sessions.^{11,23} Combined oral itraconazole and frozen surgery therapy are administered to this patient. Itraconazole was administered at a dose of 400 mg/day for 1 (one) week (pulse dose) and then followed with resting for 3 (three) weeks and can be conducted in some cycles. The administration of pulse dose is intended by giving large dose intermittently to improve therapeutic effect and to reduce the side effect. Frozen surgery or cryotherapy is administered in 1 (one) cycle for 60 seconds per week, constituting a good therapeutic option in chromoblastomycosis cases.

The management of chromoblastomycosis can be monitored with clinical presentation, supported with examination on skin scraping with KOH 10%, and or histopathology. However, to find out whether the lesion, in this case, has been cured or is potentially recurrent. A repeated examination is required in the third or fourth month of therapy.²³ In this case, the patient was followed monthly and got clinical improvement. KOH 10% examination on the third month found no spore or Medlar body appearance (Figure 8).

CONCLUSION

This case reported a chromoblastomycosis case in a male farmer, 70 years old. The diagnosis is established

based on history, physical examination, histopathological examination, and fungal culture examination. We found Medlar body / sclerotic body / round-or oval-shaped single and or colony copper penny with blackish-brown thick wall. The patient was treated with combined therapy of oral itraconazole 400mg (*pulse dose*) and cryotherapy for three months, resulting in good clinical improvement. Chromoblastomycosis grows very slowly and is difficult to treat with a high recurrence rate, so early diagnosis is critical.

REFERENCES

1. Hay RJ. Deep Fungal Infection. In: Wolff K, Goldsmith LA, Katz SI, Gilchrist BA, Paller AS, Leffell DJ, editor. Fitzpatrick's dermatology in general medicine, 8th Ed. New York: McGraw Hill; 2008:1831-5.
2. Sutton DA, Rinaldi MG, Sanche SE. Dematiaceous fungi, In Anaissie EJ, McGinnis MR, Pfaller MA, editor. Clinical Mycology. 1st Ed. New York: Churchill Livingstone; 2009. pp. 329-54.
3. Queiroz-telles F., Hoog S.D., Santos W.C.L, Salgado C.G, Vicente V. A., Bonifaz A., Roilides E., Xi L., Pedrozo C.E., Azevedo S., Silva M.B., Pana Z.D., Colombo A.L, and Walsh T.J. Chromoblastomycosis: a Clinical Microbiology review. American Society for Microbiology; 2017.
4. Sansan MV, Tejo BA, Muliando N, Dharmawan NA, Mawardi P, Julianto I. Tinjauan retrospektif kasus infeksi kulit di Poliklinik Kulit dan Kelamin Rumah Sakit Dr.Moewardi (RSDM) Surakarta. Jurnal Medika Moewardi. 2013; 2(1): 9-17.
5. Anaissie EJ, McGinnis MR, Pfaller MA, Editor. Clinical mycology. 2nd Ed. Philadelphia: Elsevier Incorporation; 2009. p.344-6.
6. Kim M, Lee S, Sung H, Won C, Chang S, Lee M, et al. Clinical analysis of deep cutaneous mycoses: a 12-year experience at a single institution. Mycoses. 2012; 55: 501-6.

7. Samaila M, Abdullahi K. Cutaneous Manifestation of Deep Mycosis: An Experience in a Tropical Pathology Laboratory. *Indian J Dermatol.* 2011; 56(3): 282-6.
8. Kazemi A. An Overview on the Global Frequency of Superficial/Cutaneous Mycoses and Deep Mycoses. *Jundishapur J Microbiol.* 2013; 6(3): 202-4.
9. Abhisiek D, Gharami RC, Datta PK. Verrucous plaque on the face: what is your diagnosis? *Dermatology Online Journal*, 2010; 16(1).
10. Pawel M. Krzdak, Malgorzata Pindycka-Plaszcznska, Michal Piaszczyński. Chromoblastomycosis. *Journal Postepi Dermatologii Alergologii Poland.* 2014; 5: 310-321.
11. Queiroz-tells, Flavio, Phillippe Esterre, et al. Chromoblastomycosis: an Overview of Clinical Manifestation, Diagnosis, and Treatment. *Medical Mycology*; 2009: 47: 3-15.
12. Ameen M. Chromoblastomycosis: clinical presentation and management. *Clin and Exp Dermatol.* 2009; 34: 849–854.
13. Trancoso A, Bava J. Chromoblastomycosis. *New England Journal Medicine*, 2009: 361:22.
14. Momin YA, Raghuvanshi SR, Lanjewar DM. Cutaneous chromoblastomycosis. *Bombay Hospital Journal.* 2008; 50:299-301.
15. Baddley JW and Dismukes WE. Chromoblastomycosis. In: Kauffman CA, Pappas PG, Sobel JD, Dismukes WE, editors. *Essentials of Clinical Mycology*. 2nd ed. New York: Springer Science Business Media; 2011: 427-31.
16. Bobba S. Case Study: chromoblastomycosis. *J Trop Dis.* 2014; 2 (4): 1-2.
17. Hay RJ, Ashbee HR. Subcutaneous Mycoses. In: Burns T, Breatnach SM, Cox N, Griffiths C, editor. *Rook's Textbook of Dermatology*, 8th Ed. Massachusetts: Blackwell publishing; 2010: 36-69.
18. Djuanda A. Tuberkulosis kutis. In: Djuanda A, Hamzah M, Aisah S, editor. *Ilmu Penyakit Kulit dan Kelamin*. Fifth Edition. Jakarta: Balai Penerbit FKUI, 2008; pp. 64-72.
19. Francisco GB, Eduardo G. Cutaneous Tuberculosis. *Clinics in Dermatology.* 2007; 25: 173–180.
20. Schwartz RA, Barran EZ. Chromoblastomycosis. last update: February 11, 2008; Access from www.emedicine.com.
21. Kayasatha BMM, Shrestha R, Shrestha Pan, Karki A. Chromoblastomycosis mimicking Squamous Cell Carcinoma: a case report. *Nepal Journal of Dermatology, Venereology & Leprology*; 2009; 8(1): 22-26.
22. Roy AD, Das D, Deka M. Chromoblastomycosis – A clinical mimic of squamous carcinoma. *Australas Med J*; 2013; 6(9): 458–460.
23. Queiroz-telles F. Chromoblastosis: a Neglected Tropical Disease. *Rev Institution Medical Tropic Sao Paulo*; 2015.
24. Ahsan M.K., Al Attas K.M, Burak M.A., Al-Sheikh A.M, and Bajawi S.M. Hidden under a cauliflower-like growth: A case of cutaneous chromoblastomycosis and response to combination therapy. *Journal of Dermatology & Dermatologic Surgery*; 2017.